

CONSENSUS STATEMENT

HFSA/SAEM/ISHLT clinical expert consensus document on the emergency management of patients with ventricular assist devices



Michael M. Givertz, MD,^a Ersilia M. DeFilippis, MD,^a Monica Colvin, MD,^b Chad E. Darling, MD,^c Tonya Elliott, RN, MSN,^d Eman Hamad, MD,^e Brian C. Hiestand, MD,^f Jennifer L. Martindale, MD,^g Sean P. Pinney, MD,^h Keyur B. Shah, MD,ⁱ Juliane Vierecke, MD,^j and Mark Bonnell, MD^k

From the ^aBrigham and Women's Hospital, Harvard Medical School, Boston, Massachusetts, USA; ^bUniversity of Michigan Medical Center, Ann Arbor, Michigan, USA; ^cUMass Memorial Medical Center, Worcester, Massachusetts, USA; ^dMedStar Washington Hospital Center, Washington, District of Columbia, USA; ^eTemple University Hospital, Philadelphia, Pennsylvania, USA; ^fWake Forest Baptist Medical Center, Winston-Salem, North Carolina, USA; ^gKings County Hospital/SUNY Downstate, Brooklyn, New York, USA; ^hMount Sinai Medical Center, New York, New York, USA; ⁱVCU Pauley Heart Center, Richmond, Virginia, USA; ^jUniversity of Cincinnati College of Medicine, Cincinnati, Ohio, USA; and ^kMclaren Greater Lansing, Lansing, Michigan USA.

KEYWORDS:

mechanical circulatory support;
ventricular assist device;
heart failure;
emergency medicine;
destination therapy

Mechanical circulatory support is now widely accepted as a viable long-term treatment option for patients with end-stage heart failure (HF). As the range of indications for the implantation of ventricular assist devices grows, so does the number of patients living in the community with durable support. Because of their underlying disease and comorbidities, in addition to the presence of mechanical support, these patients are at a high risk for medical urgencies and emergencies (Table 1). Thus, it is the responsibility of clinicians to understand the basics of their emergency care. This consensus document represents a collaborative effort by the Heart Failure Society of America, the Society for Academic Emergency Medicine, and the International Society for Heart and Lung Transplantation (ISHLT) to educate practicing clinicians about the emergency management of patients with ventricular assist devices. The target audience includes HF specialists and emergency medicine physicians, as well as general cardiologists and community-based providers.

J Heart Lung Transplant 2019;38:677–698

© 2019 Dr. Michael M. Givertz. Published by Elsevier Inc. on behalf of International Society for Heart and Lung Transplantation. All rights reserved.

I. Overview of ventricular assist devices

Over the past 2 decades, mechanical circulatory support (MCS) has offered a major advance in the treatment of patients with end-stage HF.¹ Currently, there are three

recognized indications for the use of left ventricular assist devices (LVAD): (1) bridge to transplantation (BTT); (2) destination therapy (DT) for patients not considered eligible for heart transplant; and (3) bridge to myocardial recovery allowing reverse remodeling.²

The goals for patients with refractory HF who receive an LVAD as a BTT include improving symptoms, reducing hospitalizations for worsening HF, and lowering mortality.³ While approximately 33% of patients will receive a heart transplant within 1 year of LVAD implantation, the majority will require support for 6–36 months while awaiting a donor heart. Moreover, LVAD therapy has been shown to improve the New York Heart Association functional class as well as

This article is published in the *Journal of Cardiac Failure* and the *Journal of Heart and Lung Transplantation* after review and approval by the Heart Failure Society of America and the International Society of Heart and Lung Transplantation.

Reprint requests: Michael M. Givertz, MD, Cardiovascular Division, Brigham and Women's Hospital, 75 Francis Street, Boston, MA 02115. Telephone: +1-617-525-7052. Fax: +1-617-264-5265.

E-mail address: mgivertz@bwh.harvard.edu

6-minute walk distance and quality of life.⁴ Similar improvements have been demonstrated in the growing population of patients, mostly older, receiving devices for DT.

Volumes and survival

The Interagency Registry for Mechanically Assisted Circulatory Support (INTERMACS) was initiated as a public-private partnership among the National Heart, Lung, and Blood Institute, hospitals, and industry to collect prospective data regarding clinical experiences with ventricular assist devices. As of January 1, 2018, INTERMACS became part of the Society of Thoracic Surgeons National Database. According to the eighth annual report, there were a total of 22,866 ventricular assist device (VAD) implants from June 2006 to December 2016.⁵ Of these, 18,978 were primary implants for left ventricular support. Most recently, INTERMACS has partnered with a collaborative of primarily European-based registries and a Japanese registry—referred to collectively as the ISHLT Mechanically Assisted Circulatory Support registry—to provide international data on the volumes and outcomes with MCS. Updated national and international data are available online at www.uab.edu/medicine/intermacs, www.isHLT.org/registries/international-registry-for-mechanically-assisted-c, and www.ncbi.nlm.nih.gov/pubmed/28942783.

LVADs offer superior survival when compared with optimal medical management in patients who are ineligible for cardiac transplantation. For continuous-flow devices implanted since 2008, the overall 1-year survival is 81%, and 2-year survival is 70%.⁵ An era effect on survival has also been identified and is most apparent when comparing the early era of 2008-2012 with the more recent era. LVAD implantations for DT have risen; between 2015 and 2016, 49.8% of the LVADs were implanted for DT.⁵ More recently, the MOMENTUM 3 trial compared the HeartMate 3, a magnetically levitated centrifugal flow pump to the HeartMate II, an axial flow pump. At 2 years, survival free from disabling stroke or reoperation to replace or remove a malfunctioning device was 79.5% for the centrifugal device vs 60.2% for the axial flow device ($p < 0.001$),⁶ and actuarial all-cause survival at 2 years was 88.0% and 84.7%, respectively ($p = 0.16$).

Evolution of LVADs

Contemporary LVADs typically consist of an “inflow” cannula that drains the left ventricle and an “outflow” graft to a central artery. Most commonly, this outflow graft returns blood to the ascending aorta, less commonly to the descending aorta and occasionally to the subclavian artery. Other internal components consist of the pump itself and part (20-30 cm) of the driveline, which contains duplicate wires that power and control the pump. External components are a controller and an external power source. The first durable LVAD approved for DT was the HeartMate XVE in 2002.⁷ This was a large, intracorporeal device that operated in a fill-to-empty mode and maintained the pulsatile nature of the physiologic cardiac cycle.⁸ These devices were prone to mechanical

failure with limited device durability requiring reoperation for device exchange. Despite several design enhancements to the HeartMate XVE, durability was <5% at 2 years.⁸⁻¹⁰

Current LVADs provide continuous flow (CF) through a rotary pump, resulting in blood flow with reduced or no pulsatility.¹¹ The HeartMate II (Abbott) was the first continuous-flow LVAD approved in the US for BTT in 2008 and for DT in 2010. The HeartWare HVAD (Medtronic) is a centrifugal flow pump approved for BTT in 2012 and DT in 2017. The newest CF device is the HeartMate 3 (Abbott), a fully magnetically levitated pump with an artificial pulse (e.g., once every 2 seconds, the pump automatically modifies its speed) and reduced risk of thrombosis and stroke, which was approved for BTT in 2017 (Figure 1).^{12,13} The CF devices are smaller, quieter, and more durable, which makes them more suitable for DT.¹¹ Their smaller size has also allowed for an increasing number of adults as well as children to be candidates for MCS.⁸ Some basic characteristics and parameters of the 3 main commercially available devices are shown in Figure 2. For more information, readers are referred to individual manufacturer’s instructions for use.

II. Clinical aspects specific to VAD patients

Assessing equipment

The first steps in evaluating a patient with a VAD are to determine the make and model of the pump and the status

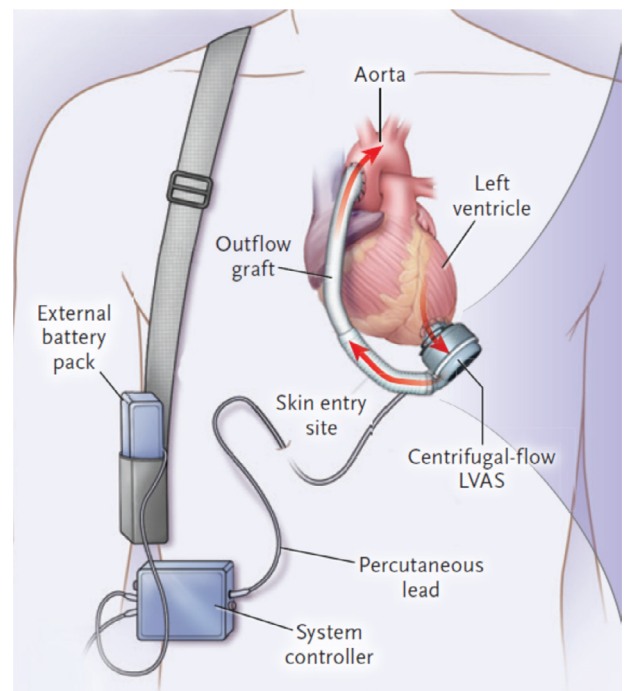


Figure 1 Components of a typical left ventricular assist device (LVAD). A continuous flow a (CF) LVAD consists of a pump connected to the cardiac apex and ascending aorta via an inflow cannula and outflow graft, respectively, a percutaneous driveline that exits the skin on the right, and a system controller that is typically worn on a belt. Power to the controller and pump is provided by external batteries or a power-based unit. Adapted from Mehra et al,¹² with permission.



Figure 2 Left ventricular assist device (LVAD) controllers with an alarm display. (A) HeartMate II pocket controller showing controller display/buttons (top) and driveline fault alarm with a yellow wrench (below). The patient is instructed to contact the ventricular assist device (VAD) team for further advice on troubleshooting and management. (B) HeartWare HVAD with controller display/buttons (top) and low battery alarm (below). The patient is instructed to replace the battery. (C) HeartMate 3 pocket controller (top) and red heart alarm (below). The patient is instructed to call the hospital contact (LVAD program).

of the equipment. Some patients may wear a medical alert bracelet, but as not all patients do, a rapid assessment of the VAD equipment will ensure proper treatment. All controllers are branded with the model name of the system, and this can be located by opening the pouch or pocket with the controller. Currently, all implantable LVADs have an external driveline connected to a control device and power source. Therefore, it is important to locate the driveline, which allows the pump to receive information and power to run the VAD system. This cable should be attached at one end to the implanted VAD pump and connected properly to

the controller. One should ensure that the driveline is not obviously damaged (i.e., exposed or severed wires).

There is a dressing on the abdominal wall where the cardiac surgeon tunneled the driveline through the skin during VAD implantation, and one should confirm that the dressing is dry and intact. Patients are instructed to secure the driveline to prevent trauma to the site in the event of accidental pulling on the driveline or external equipment. Some patients wear an abdominal binder, but most wear an anchor device that was originally designed to secure Foley catheters or vascular access devices. If the driveline is not

immediately apparent, the examiner should look under binders and dressings so that the entirety of the line can be inspected, especially if the pump is not running. Whenever possible, the anchor or binder should be kept in place during transport and treatment to assist with the stabilization of the driveline. If the driveline dressing is removed, sterile technique should be used to replace it.

The controller is a device that is connected to both the driveline and power source. This unit will be of a different size, shape, and configuration depending on the manufacturer and model (Figure 2). Patients employ various strategies to carry their externals ranging from “fanny” packs, vests, purses, and holsters, to other manufacturer-provided or homemade carriers. It is important to follow the driveline to the controller and extract as much as necessary to assess its connections and function. If there is an apparent disconnect as indicated by an audible alarm (discussed below), search for any and all carrying devices so as to locate the controller and reconnect it to the driveline.

The controller communicates with the pump, displays pump parameters (e.g., speed, flow, and power), and alarms for both advisory and hazardous conditions. The controller requires 2 power sources. These can be either 2 batteries or 1 battery in addition to an AC/DC adapter. Typically, when patients are active, they rely on dual batteries for power supply, which can provide anywhere from 8 to 12 hours of support. When sleeping, or resting at home, many patients use an electrical output for power source. Patients with VADs should always have spare batteries accessible.

The percentage of charge remaining in each battery can be determined by pushing the button on the top of the battery. Percentage of charge is displayed with bars: if all the lights are displayed, 100% of the batteries are charged; if three lights are displayed, 75% charge remains; and so on.

All patients should have an extra controller and 4-8 batteries as backup equipment. One should exchange the primary controller (attached to the patient) for the backup controller only when indicated by alarms on the controller, such as “Controller Fault, Change Controller” and under the guidance of a clinical provider trained to perform this exchange. Pre-hospital personnel are advised to transport as much of the VAD equipment as possible with the patient so advanced troubleshooting can be performed at the VAD center.

Vital signs

Continuous-flow physiology and the resulting narrow arterial pulse pressure create a challenge in assessing and measuring vital signs, especially with traditional methods. Variability in native heart function may contribute to pulsatile flow that can result in a palpable pulse, although this is typically absent. If no pulse is found, this is still a normal state for most patients with CF pumps.

Selecting a method to measure the blood pressure is a source of debate as non-invasive methods are designed to measure systolic and diastolic pressures. The gold standard for measuring CF blood pressure is an arterial line, which is not available in the pre-hospital setting.¹⁴ Correlation

studies seeking to determine a reliable non-invasive method found that most automatic and manual blood pressure measurements are not sensitive enough to detect such small differences in systolic and diastolic blood pressure.¹⁵ Therefore, the use of vascular Doppler sonography has been adapted by most VAD programs to assess blood pressure. It is commonly assumed that the first sound heard is approximately equivalent to the mean arterial pressure (MAP), yet studies show this may be closer to the systolic pressure.¹⁴ The artificial pulse in the HeartMate 3 pump complicates the detection of MAP and may result in variability between captured measurements.¹⁶ Despite these limitations, we suggest using the Doppler opening blood pressure as a surrogate for the MAP, with current ISHLT guidelines recommending a mean blood pressure goal of ≤ 80 mm Hg.¹⁷ Although palpating a pulse may be unreliable or impossible, standard electrocardiogram (ECG) monitoring should be used to obtain heart rate and rhythm.

In addition, the low pulse pressure makes it difficult to assess pulse oximetry,¹⁸ as pulse oximeter technology is based on pulsatile flow. Therefore, a routine digital device may not detect any reading or may be inaccurate in patients with CF VADs, who do not demonstrate arterial pulsatility. Similar to patients with poor peripheral circulation, it is important to assess waveform on the pulse oximetry system when evaluating the reliability of the reading. In the pre-hospital setting, simple clinical signs, such as whether the patient is pink or blue, awake or somnolent, are important in assessing physiology.

VAD parameters

VAD parameters should be considered the “vital signs” of the pump. The controller displays numbers that capture pump function and flow. A typical display shows the flow in liters per minute, rotations per minute of the moving part inside the pump, and the power consumed (W). The VAD flow is calculated, not measured, by the pump and is derived from speed and power consumption. The flow calculation is directly proportional to power consumption, therefore, factors that affect power (i.e., thrombus on the impeller [more work to spin at the same speed]) will change the flow displayed. The flow on the controller may not represent the true output of blood to the patient. Some VAD models (e.g., HeartMate II and 3) have an additional parameter, the pulsatility index (PI), that provides useful information regarding pump filling. Trends in the PI can assist providers in assessing the impact of therapies or conditions that expand or contract intravascular volume. The controller will also display any alarm conditions that may affect pump function. These numbers should be monitored frequently during the pre-hospital treatment with trends and alarms reported to the implanting center or VAD clinician.

Device alarms

The controller has visual and auditory alarms that indicate problems with the VAD pump, controller, connections, or

the power supply. Some alarms indicate advisory conditions, such as low batteries, and are resolved easily. The controller will also announce hazardous alarms when there are more critical issues that may imminently affect pump function. Low-flow and high-power alarms will be discussed later. Address alarms by first looking at the controller and reading the condition (Figure 2). For further information or instructions, we recommend contacting the implant center or the manufacturer's clinical specialist or accessing online instructions for use. If available, a member of the VAD team can send log files for analysis by clinical engineers and review waveforms on certain devices.

Anti-thrombotic therapy

Anti-thrombotic therapy is necessary for all patients with VADs but is a challenging balance between two opposing complications: pump thrombosis and bleeding (gastrointestinal, nasal, intracranial, and menstrual). There are no clinical trials comparing anti-coagulation regimens in patients with VADs; therefore, treatment relies on manufacturer's recommendations, experience, and anecdotal reports. Implanting centers generally have their own clinical practice guideline for anti-coagulation management.

Typically, patients are maintained on warfarin with an international normalized ratio (INR) target of 2.0-3.0 and aspirin 81-325 mg daily, although lower INR targets are being tested.¹⁹ Some VAD programs use dipyridamole or clopidogrel as additional anti-platelet therapy (e.g., in patients with a history of threatened pump thrombosis or transient ischemic attack), but there is no supportive data. The reversal of warfarin with vitamin K, fresh frozen plasma, or prothrombin concentrate complex may be considered when treating life-threatening bleeding events or preparing for emergent surgery. However, this should only be performed after contacting the implanting center for recommendations. Rebound blood clotting can result in pump thrombosis and the need for surgical exchange of the pump.

III. Pre-hospital management and emergency management system challenges

Importance of "pre-release" community education

Sending home patients who are pulseless and dependent on electricity requires that hospitals educate local providers to be aware of VAD patients in their community and resources available to care for them. Consensus guidelines recommend the use of "field guides" as a resource for pre-hospital education.¹⁷ These guides have been written by emergency management system (EMS) providers and VAD coordinators to provide a quick reference tool when responding to a VAD emergency.²⁰ There is a page for each model of device approved for home use. The color borders allow implanting centers to color code tags on the equipment with the color that matches the border on the field guide for each device. For example, the HeartMate 3 page has a green border, so the luggage tags and medical alert bracelets

are green. The current version of the field guides can be accessed online at www.mylvad.com/medical-professionals/resource-library/ems-field-guides.

Patients and caregivers are educated before hospital discharge following a VAD implant. They must demonstrate the ability to care for external components, change the driveline dressing, respond to alarms and emergency conditions, and change power sources without extended interruption of power. Communication between the family and the VAD team is essential, often via a VAD pager, text, and/or e-mail. Having a pre-determined emergency plan is the key to any successful VAD program. Once an emergency occurs, there should be a mechanism to contact the VAD team, so they may assist in directing further patient care and triaging to the appropriate facility.

Unfortunately, some patients and caregivers have been unable to perform duties during emergencies because of anxiety induced by the VAD alarms and the critical nature of the event. In other circumstances, the patients may be alone and unable to communicate because of the nature of the emergency (e.g., trauma, stroke), and the VAD team must rely on EMS or outside emergency department (ED) providers to make the first contact. Pre-hospital management of VAD emergencies can be streamlined by the use of field guides, contact with the implanting center, and the establishment of a transport plan that expedites return of the patient to the implant center.

Field assessment and transport

A patient with a VAD should be evaluated first and foremost as any other patient. The emergency provider should take a focused history and perform a targeted physical examination paying attention to findings specific to patients with implantable blood pumps. Basic cardiac life support and advanced cardiac life support (ACLS) algorithms still apply,²¹ with the understanding that most patients with VADs are pulseless at baseline. In addition, patients may remain hemodynamically stable despite ventricular arrhythmias (see below). If the patient has no neurological deficits, he or she should be asked about any preceding symptoms (e.g., shortness of breath, chest pain, headache, or blood in the urine or stool), the model of his or her VAD, and if any alarms have sounded. Patients may be able to identify equipment malfunctions or driveline concerns. The on-site team should attempt to contact the implanting VAD center as soon as clinically possible and transfer the patient to a VAD-capable center as soon as he/she is stabilized.

An assessment of hemodynamics includes both physical exam findings, as well as an evaluation of the VAD equipment (Figure 3). Perfusion can be determined based on the patient's pallor, perceived extremity perfusion (warm vs cold), neurological status, and capillary nail refill. Auscultation of the chest should reveal the presence of a VAD hum. The driveline typically exits the right upper quadrant, sometimes the left, and rarely behind the ear. A focused examination should evaluate for signs of HF such as elevated jugular venous pressure, crackles or diminished

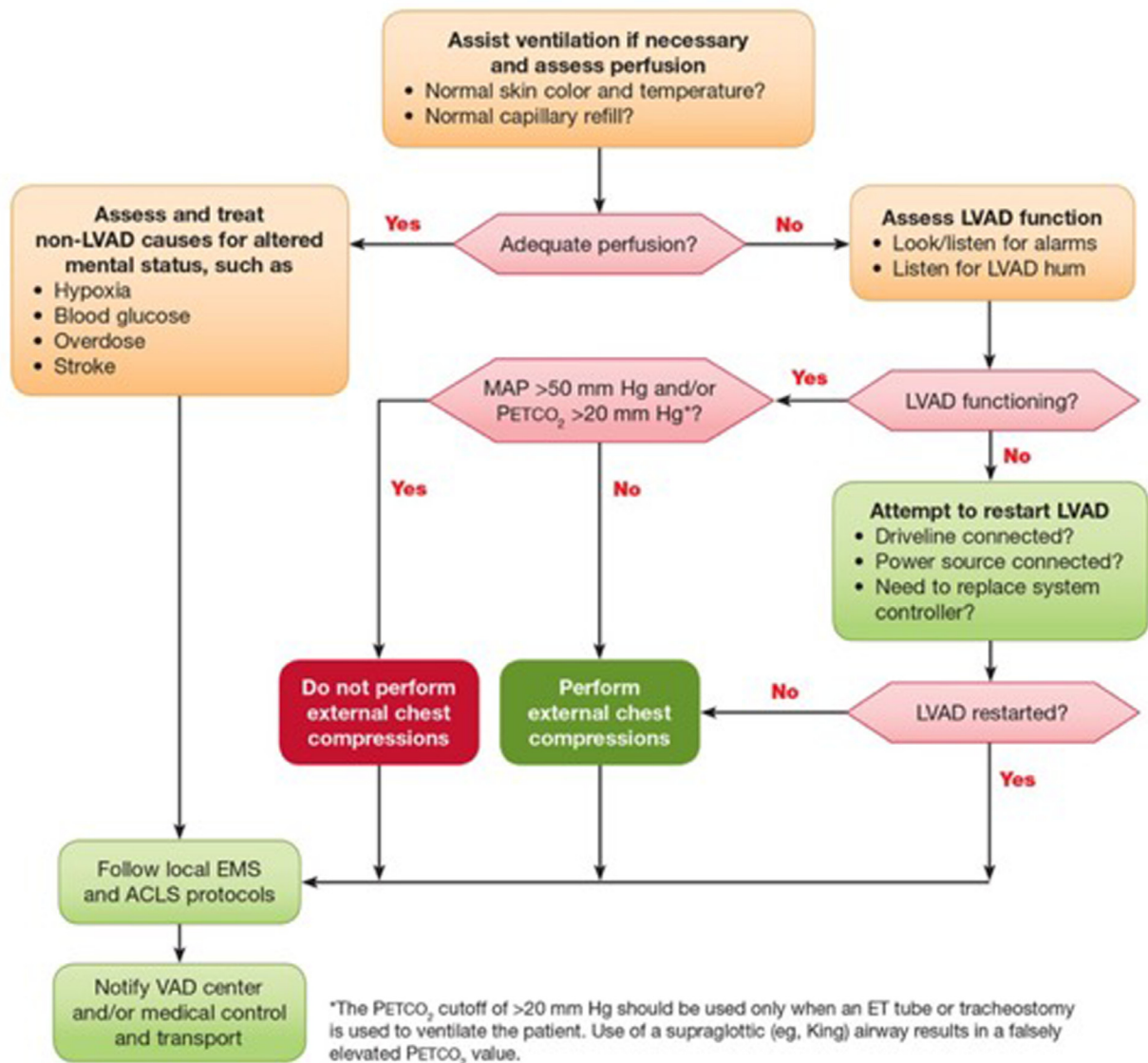


Figure 3 Assessment of the unresponsive left ventricular assist device (LVAD) patient. Shown is the American Heart Association (AHA) algorithm for the assessment of an LVAD patient who is unresponsive or has altered mental status.

breath sounds, hepatomegaly, ascites, and lower extremity edema. As discussed below, gastrointestinal (GI) bleeding and epistaxis are common in patients with VADs, so evidence of bleeding from the nose, abdominal distension, or frank melena should be noted.

In general, if both batteries are disconnected or if the driveline is disconnected, the pump will not function (with the exception of the HeartMate II and 3 pumps for which the pocket controller provides an additional 15 minutes of power if disconnected from the power source). If the pump is not operating or alarming, the connections between the controller, batteries, and patient should be checked first and reconnected if needed. Then, one should check for alarms and replace batteries or the controller if necessary. Whenever possible, the patient's charging station, all of their batteries, and recent medical records (e.g., INR readings and VAD performance documentation) should be taken to assist with hospital care.

Should it be necessary to transport the VAD patient to the nearest local hospital without VAD capability, it is

imperative to facilitate communication between the local hospital and the implanting center. A collaborative course of action can then be implemented that best serves the unique needs of the patient. Together, these 2 teams can assess the salient issues in most emergency situations and determine whether the specific problem can be dealt with initially in a general hospital setting or requires emergent transfer to a VAD-capable center (Table 2). Pocket-sized emergency cards and larger ones for use in the home have been developed to help facilitate these initial interactions. The patient is advised to display the larger one at an easily recognizable access point (e.g., in the home entrance or on the refrigerator). In addition, most VAD centers offer regular training to local fire department, police, and EMS personnel.²²

All emergencies that may require surgery should also be considered high acuity. If the patient with a VAD is hemodynamically unstable, has pump stoppage, or an intracerebral event, he/she should be stabilized at the nearest hospital and then transferred. VAD centers have personnel and other

Table 1 Common Emergencies in Patients With Ventricular Assist Devices

VAD-specific emergencies	VAD-related emergencies	VAD unrelated emergencies
Heart failure	Arrhythmias	Abdominal pain
Left heart failure	Atrial fibrillation	Blunt and
Right heart failure	Ventricular	penetrating
Mechanical failure	tachycardia	trauma
Driveline	Ventricular	Hypovolemia
Pump stoppage	fibrillation	Infection
Pump thrombosis	Bleeding	Sepsis
	Epistaxis	
	Gastrointestinal	
	Cardiac arrest	
	Cardiac tamponade	
	Infection	
	Driveline	
	Pump pocket	
	Stroke	
	Hemorrhagic	
	Ischemic	

VAD, ventricular assist device.

sub-specialists (i.e., infectious disease, gastroenterology, neurosurgery) beyond the core of cardiac surgeons, cardiologists, and coordinators with specialized experience in the management of VAD patients. Complicated infections should be treated in a VAD center irrespective of the infectious source.

IV. Medical emergencies in patients with VADs

Cardiac arrest

In patients with continuous-flow LVADs, cardiac arrest may be surprisingly difficult to ascertain clinically, or to differentiate from conditions resulting in syncope or impaired consciousness. Pulselessness and the inability to obtain a blood pressure with automatic devices represent the normal state for patients with LVADs. Even in the inpatient setting on specialized cardiac units, the time to initiation of resuscitation is prolonged in patients with LVADs with cardiac arrest compared with other medical patients.²³ In the unconscious patient, the absence of mechanical hum on precordial auscultation, inability to obtain a Doppler signal on manual blood

Table 2 Clinical Situations Requiring Emergent Transfer to the Primary VAD Center

Cardiac tamponade
Mechanical VAD failure
Need for emergency non-cardiac surgery
Neurologic events
Hemorrhagic stroke
Ischemic stroke
Pump thrombosis

VAD, ventricular assist device.

pressure measurement, and cardiac standstill on bedside ultrasound (if available) are diagnostic of true cardiac arrest. However, if a pump is fully functional, a mechanical hum may still be heard. While resources such as point-of-care ultrasound and Doppler echocardiography may be available in the ED or on an inpatient unit, these resources are generally not available to pre-hospital EMS personnel and certainly not to bystanders who might be the first to respond to a collapsed patient. In the pre-hospital setting, given unresponsiveness, apnea, and absence of mechanical hum, one should assume cardiac arrest has occurred, and cardiopulmonary resuscitation (CPR) should be initiated. Assessment of cardiac rhythm with a portable monitor or ECG is indicated in all patients, although electrical interference/artifact may be present (Figure 4).

There are varying opinions regarding the efficacy and safety of performing chest compressions in patients with LVADs, with the debate informed by retrospective case series²⁴ and cohort studies.^{23,25} The primary concern is damage to or dislodgement of the cannulae or displacement of the pump, resulting in catastrophic failure and potential intrathoracic exsanguination. Garg et al²³ reported that of 9 hospitalized patients with LVADs requiring chest compressions, none survived to hospital discharge. In another limited review,²⁴ 5 of 10 patients with LVADs had neurologically intact survival after cardiac arrest. In non-survivors, no damage or dislodgement of the devices was noted. Therefore, we cautiously conclude that CPR may be beneficial, and harm has not been demonstrated. This is consistent with the American Heart Association scientific statement, which recommends bystander CPR even if an LVAD is confirmed (Figure 3).²¹ With regard to devices designed for mechanical CPR (e.g., ZOLL AutoPulse Resuscitation System, Zoll Medical Corporation, Chelmsford, MA), based on the lack of evidence in the general population and equipment concerns, we do not recommend their use.

Unstable arrhythmias

Arrhythmias, both atrial and ventricular, are common complications in the ambulatory patient with an LVAD. Some patients demonstrate electric abnormalities including ST and T wave changes or a bundle branch block at baseline. Ventricular tachycardia (VT) is common (up to 50%) in the LVAD population because of underlying cardiomyopathy, right ventricular (RV) failure, or mechanical compression of the ventricle by the inflow cannula, but it is rarely life threatening. Polymorphic or monomorphic VT due to myocardial ischemia/infarction from native coronary artery disease or coronary embolism from an aortic root thrombus is also possible.²⁶ In the HeartMate II DT study, investigators observed an arrhythmia rate (requiring intervention) of 56% in the continuous-flow group and 59% with pulsatile flow.¹¹ Studies examining hospital readmissions identify arrhythmia as the cause for readmission in 5%-8% of the patients with LVADs.^{27,28} Other studies of patients with pre-existing implantable cardioverter defibrillators (ICDs) note substantially higher rates of ventricular arrhythmia (28%-45%).²⁹⁻³¹ This subpopulation

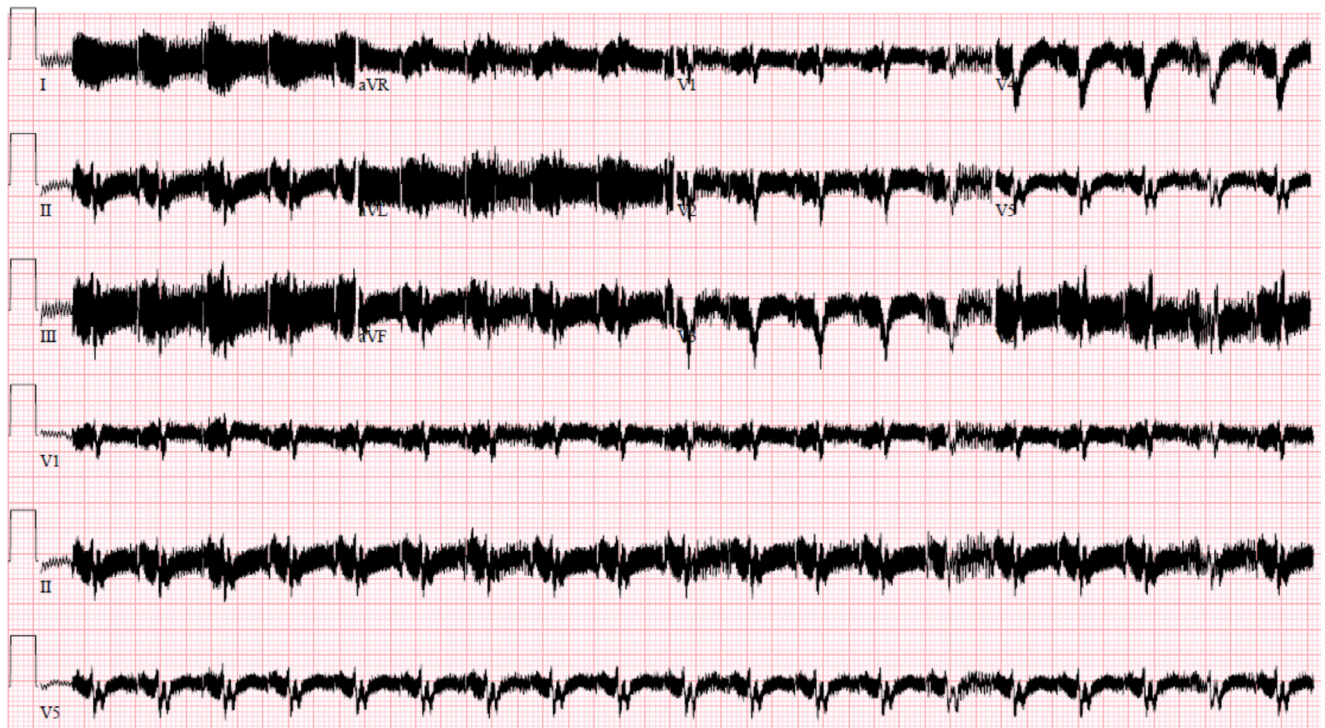


Figure 4 Representative electrocardiogram (ECG) from a patient with a left ventricular assist device (LVAD). Demonstrated is marked baseline artifact generated from the electrical pump.

may be biased toward a higher event rate, as ventricular arrhythmia before LVAD placement appears to predispose patients to arrhythmic events after surgery.^{29,30}

Because of the degree of physiologic support afforded by the LVAD, patients may present complaining only of vague fatigue, nausea, or lightheadedness with arrhythmias that would be otherwise fatal.³² Rarely, patients will be asymptomatic in the face of VT or ventricular fibrillation (VF). Long-term presence of high-grade ventricular arrhythmias can lead to RV dysfunction, hypotension, and ventricular collapse as a result of reduced left ventricular (LV) filling and inflow cannula obstruction or “suction events.” Syncope has also been reported in this setting. In an electrophysiological laboratory-based study, induced VF immediately reduced device flow by a mean of 32%.³³ Therefore, ECGs should be routinely obtained to define the presenting rhythm, even when the presenting complaint to the ED does not appear cardiac in nature. Ventricular arrhythmias should not be misattributed to “interference” from the device. For patients with intermittent symptoms and the presence of an ICD, urgent interrogation of the device is warranted to detect culprit episodic arrhythmias.

VT or VF may be tolerated for a short period, often allowing the treating physician the luxury of time to deliberate over the diagnostic and treatment plan. If point-of-care echocardiography is available, examination of the inflow cannula position within the ventricle may demonstrate the presence of an overly decompressed LV with collapse and marked septal shift, which may trigger arrhythmias. This may respond to decreasing LVAD speed, allowing for increased ventricular filling and migration of the septum away from the inflow cannula. In patients with hypovolemia, a gentle fluid bolus can enhance pre-load and prevent ventricular

collapse against the cannula during systole even in the patient with a failing RV until appropriate inotropic or other support can be initiated. In some patients, VT may be positional because of cannula orientation and may not respond to speed changes or fluids. [Table 3](#) summarizes abnormal echocardiographic findings in VAD emergencies.

Symptomatic arrhythmias should be treated according to standard ACLS protocols. Cardioversion and defibrillation are not contraindicated and may be performed without disconnection from the device, with sedation used as needed. Many patients with LVADs also have an ICD that will respond to the presence of arrhythmias, and targeted programming algorithms have been suggested to avoid inappropriate therapies and optimize functional status ([Figure 5](#)).³⁴ Antiarrhythmic agents such as amiodarone should be considered in the absence of a mechanical cause of the arrhythmia if the patient is hemodynamically stable. However, with refractory or hemodynamically significant ventricular arrhythmias, cardioversion/defibrillation will frequently be required.³² For patients with recurrent VT resulting from heightened sympathetic tone, high-dose beta-blockers and even stellate ganglion blockade may be considered.³⁵ Uncontrollable ventricular arrhythmias can be an indication for temporary or durable RV mechanical support.^{36,37}

Myocardial infarction

Acute myocardial infarction can occur in patients with LVADs because of plaque rupture from underlying coronary artery disease or coronary embolism from ventricular or aortic root thrombus. Aortic root thrombus tends to occur early post-implant often in the setting of a sub-therapeutic

Table 3 Echocardiographic Findings in VAD Emergencies

Condition	LV diameter ^a	Aortic valve opening	Mitral regurgitation	IVC diameter	Septal position	Comments
Inappropriately low speed	↑	-/↑	↑	-/↑	Rightward	Ramping speed leads to LV decompression and AV closure
Pump thrombosis	↑	↑	↑	-/↑	Rightward	Ramping speed does not result in expected LV decompression or change in AV opening
Pump stoppage	↑	↑	↑	↑	Rightward	Reversal of flow through inflow and outflow cannulae may be demonstrated
Aortic insufficiency	↑	-	↑	-/↑	Rightward	"Moderate" AI by color flow mapping can be hemodynamically significant
RV failure	↓	↓	↓	↑	Leftward	Increased RV dimensions may be associated with moderate-severe TR
Hypovolemia	↓	↓	↓	↓	Leftward	

AI, aortic insufficiency; AV, aortic valve; IVC, inferior vena cava; LV, left ventricular; RV, right ventricular; TR, tricuspid regurgitation; VAD; ventricular assist device.

^aIncrease or decrease relative to baseline study obtained when patient clinically stable.

INR²⁶ and can be visualized by transesophageal echocardiography (TEE) or computerized tomography (CT) angiography.³⁸ Depending on the cause of acute MI, management may include percutaneous coronary intervention, intensification of anti-coagulation, or aortic root thrombectomy.³⁹ Because patients are typically fully supported by the LVAD, chest pain may be the only presenting symptom, with HF being less common. Complications can include ventricular arrhythmias (discussed above), structural defects such as papillary muscle rupture, and acute right heart failure from inferior MI with RV

involvement. In a recent case series of aortic root thrombosis, RV failure was common (67%), with 28% of patients requiring surgical right ventricular assist device implantation.²⁶

Unexplained hypotension

LVAD systems do not have a direct way to measure the amount of blood in the left ventricle, making patients vulnerable to low-flow complications and hypotension (defined

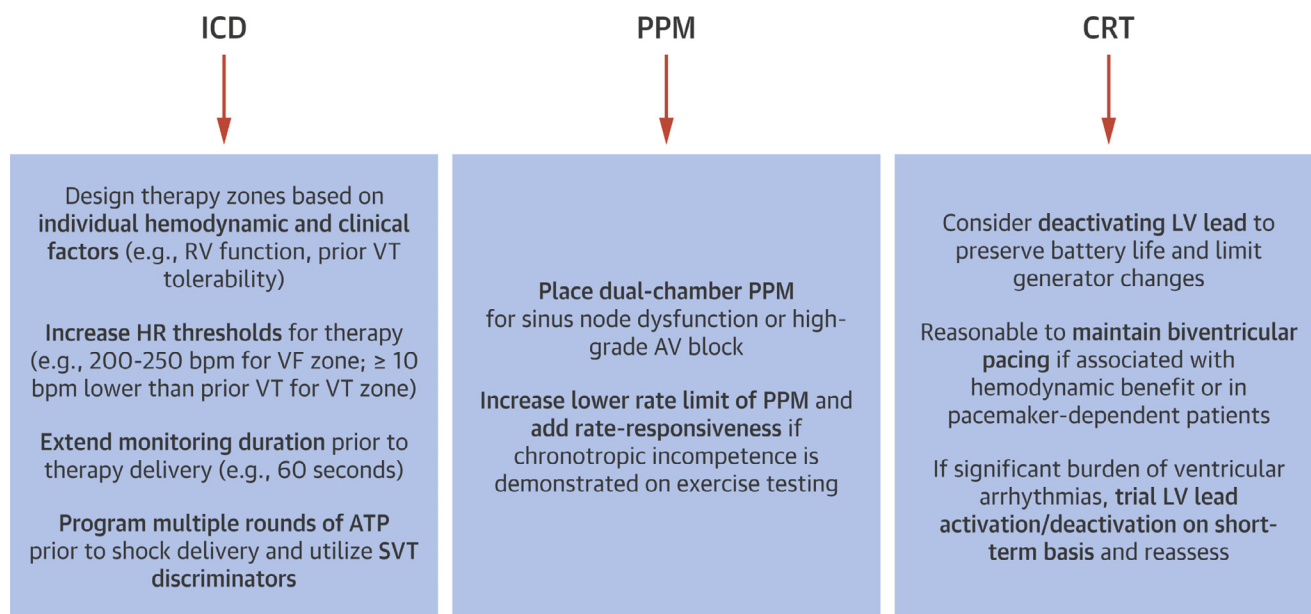


Figure 5 Unique aspects of cardiac implantable electronic device programming in patients with ventricular assist devices (VADs). There are limited data to guide the programming of cardiac implantable electronic devices (CIEDs) in patients with VADs. Because ventricular tachycardia (VT) can occur with minimal or no symptoms, the goal of implantable cardioverter defibrillator (ICD) programming is to minimize inappropriate therapies and optimize functional status. For patients with symptomatic bradycardia resulting from sinus node dysfunction or high-grade atrioventricular AV block, implantation of a permanent pacemaker (PPM) may be indicated. The benefit of cardiac resynchronization therapy (CRT) post-VAD implantation is unproven, and deactivating the left ventricular lead may help to preserve battery life. Adapted from Berg et al,³⁴ with permission.

Table 4 Differential Diagnosis and Management of Unexplained Hypotension

Cause	Signs	Intervention
Bleeding (gastrointestinal, nasal and cerebral hemorrhage)	Low hemoglobin, hematocrit and platelet count \pm elevated INR + stool guaiac Low flow	Bolus IV fluids, transfusion Hold or reverse anti-coagulation Identify and treat bleeding source
Dehydration (infection, vomiting, diuretics, poor oral intake)	Low JVP Low Flow / Low PI \pm suction	IV fluids, hold diuretics \pm decrease VAD speed temporarily to avoid suction Identify etiology and treat
Right heart failure (tamponade/effusions, PE, cannula position)	High JVP Low flow	Echo (consider RHC) Initiate inotropic support if RV failure PDE-5 inhibitors may be considered if PH present
Inadequate LVAD speed	High JVP Low flow	Echo and RHC Inadequate unloading by LVAD: high PCWP, low output Adjust pump speed
Arrhythmia	Obtain rhythm strip immediately Sudden cardiac arrest is difficult to define, as VAD patients can be awake while in VF Low flow \pm suction	Use ACLS guidelines to treat arrhythmia
Mechanical obstruction/thrombus	Elevated LDH and plasma-free hemoglobin, dark urine Low flow \pm power spike	Echo CTA to evaluate inflow and out flow cannulae Optimize anti-coagulation
Sepsis (driveline exit site, indwelling catheters or home IVs)	Elevated WBC, fever High flow because of low SVR	Hold vasodilators Add pressor support Identify source and treat

ACLS, advanced cardiac life support; CTA, computerized tomographic angiography; INR, international normalized ratio; IV, intravenous; JVP, jugular venous pressure; LDH, lactate dehydrogenase; LVAD, left ventricular assist device; MAP, mean arterial pressure; PCWP, pulmonary capillary wedge pressure; PDE, phosphodiesterase inhibitor; PE, pulmonary embolism; PH, pulmonary hypertension; PI, pulsatility index; RHC, right heart catheterization; RV, right ventricular; SVR, systemic vascular resistance; VAD, ventricular assist device; VF, ventricular fibrillation; WBC, white blood cell count.

as a MAP or Doppler opening pressure <60 mm Hg for a continuous-flow device).¹⁷ Factors resulting in pre-load reduction (e.g., hypovolemia, RV failure, and tamponade) lead to sub-optimal LV filling, which in turn can cause sub-optimal flow or suction in the inflow cannula.⁴⁰ The pump will continue to spin with a minimal ability to reduce speed to compensate for decreased volume, and instability can ensue. Many common conditions can cause hypotension in LVAD patients. Most of these conditions lead to reduced LVAD pre-load, which can trigger a low-flow alarm (Table 4).¹⁷ It must be noted that the HVAD and HeartMate 3 devices have a manually entered hematocrit, so gastrointestinal bleeding can affect the flow/power estimations if hematocrit is inputted incorrectly. However, hypertension can also lead to low flow by increasing the afterload. Low flow in the device accompanied by increasing central venous pressure should lead to consideration of RV failure as discussed below.⁴¹ For patients with an HVAD, hypovolemia is suggested by waveforms showing dampening of flow pulsatility.

Blunt and penetrating trauma

Trauma management is an algorithm-driven speciality carried out by organized teams with well-defined protocols,

and the same principles apply to the LVAD population.^{42,43} Once stabilized, a patient with an LVAD should be transported to the nearest hospital with VAD capability. Hospitals with VAD programs have already modified existing resuscitation algorithms and educated supporting personnel.

On arrival to the ED, advanced trauma life support protocol should begin with a thorough physical and focused assessment with sonography for trauma exam concomitant with VAD system troubleshooting. Cardiac surgery should also be notified given anatomic considerations related to the device. While current advanced trauma life support protocols do not account for MCS, a proposed accessory algorithm is presented (Figure 6). Given the monitoring challenges in patients with CF pumps, strong consideration should be given to early invasive blood pressure measurement and additional hemodynamic monitoring to assess patient stability. In parallel, the VAD team should interrogate the VAD equipment to confirm proper functioning and examine the device history for malfunction, including alarms and power disconnects. A standard chest X-ray will provide evidence of pump position and integrity of the driveline by comparison with previous images. A targeted X-ray of the driveline should be performed to ensure that there has been no break in the wires (Figure 7). If so, the manufacturer representative/engineer should be notified immediately, as most extracorporeal wire fractures can be

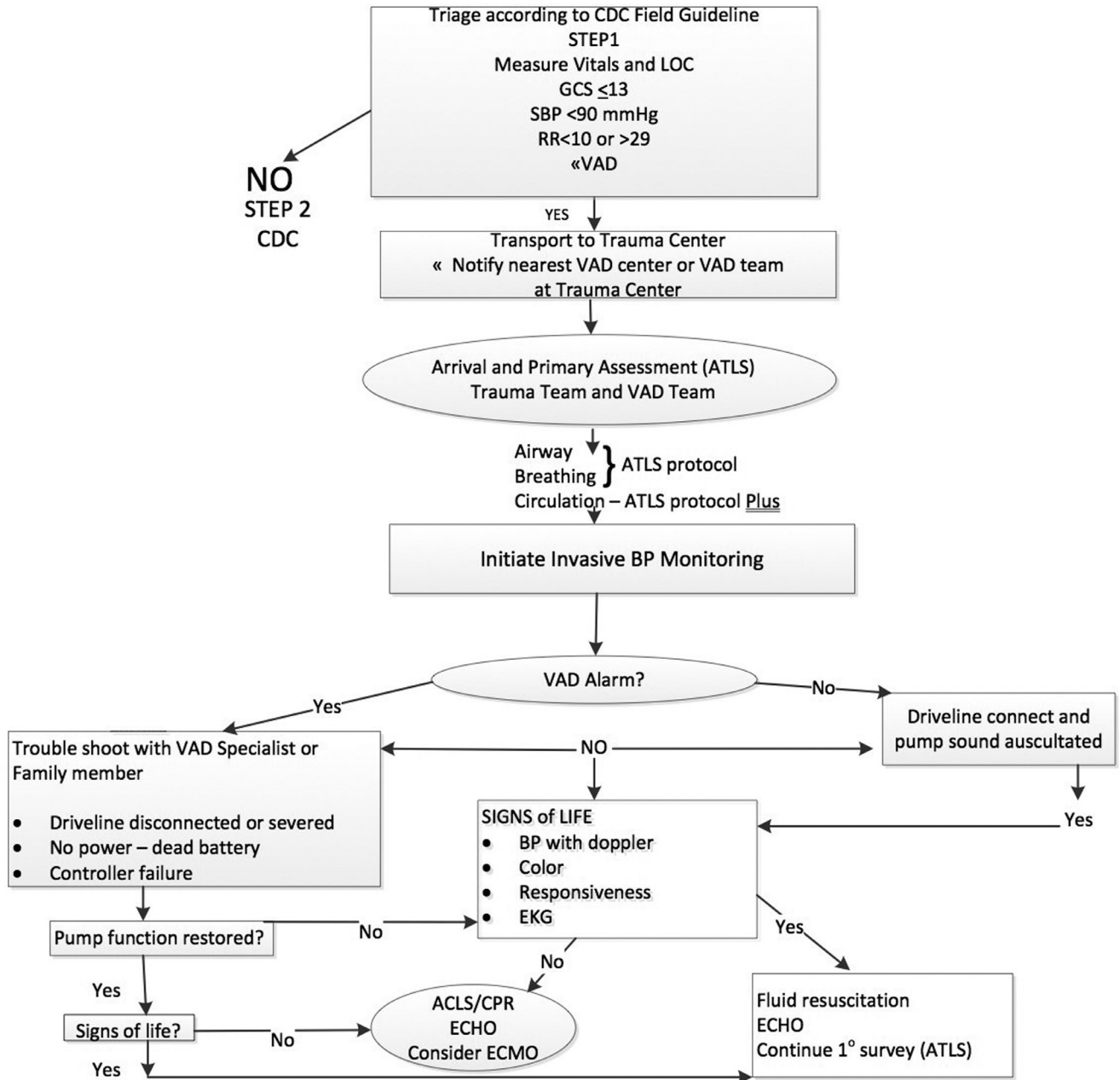


Figure 6 Proposed algorithm for management of trauma in a patient with a left ventricular assist device (LVAD).

safely repaired at the bedside.⁴⁴ Intracorporeal wire fractures may require VAD exchange.

Echocardiography is an important addition to the initial assessment in VAD patients. It can demonstrate proper pump placement, disturbances in the blood flow pathway, and change in RV function. Patients with durable MCS cannot undergo magnetic resonance imaging, but other imaging modalities such as CT or invasive angiography are not limited by device presence, although some windows may be obscured by the pump. Standard laboratory assessment including lactate dehydrogenase (LDH) or plasma-free hemoglobin levels should be obtained to assess for hemolysis, which may provide clues with respect to the more subtle disturbances in the blood flow pathway.

Patients will fall into one of 5 groups initially based on hemodynamic stability and pump function with treatment

guided by a proposed algorithm (Table 5). If the patient is hemodynamically unstable but the pump is functional, one should proceed to surgery, with appropriate monitoring including intraoperative TEE, cardiac anesthesia with VAD expertise, and perfusion or other VAD-trained staff. If the patient is hemodynamically unstable with a non-functional pump, one should assess for patient salvageability and an attempt to restart the pump should be made. Temporary MCS, including extracorporeal membrane oxygenation may be needed to restore circulation, followed by a secondary assessment of patient stability and likelihood of meaningful recovery. In all cases, particularly in those where the pump is non-functional, emotional support of the patient and family is paramount, and bringing in a grief counselor or providing pastoral support and palliative care to assist with decision making is advisable.

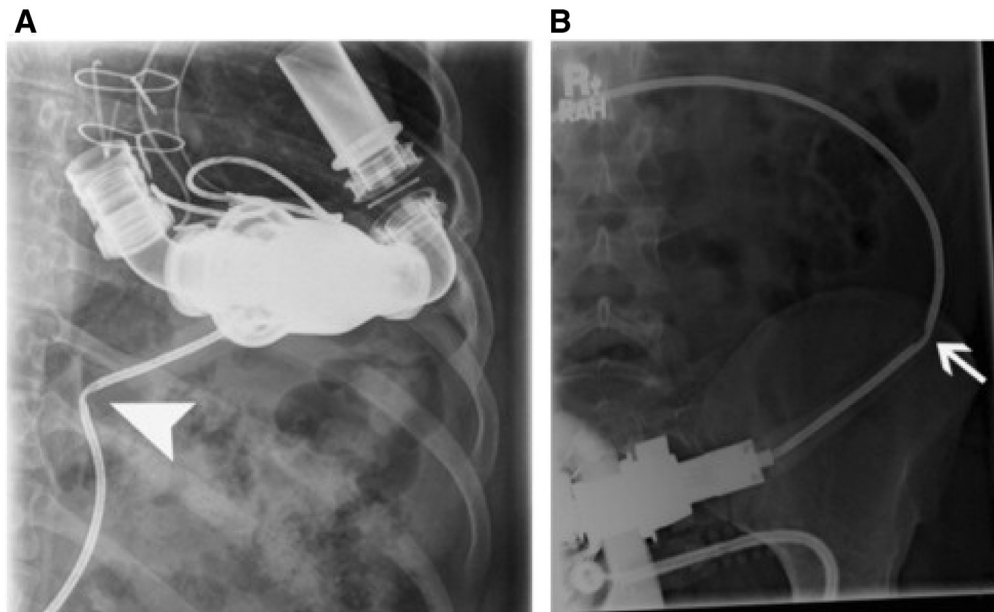


Figure 7 Imaging to look for damage in the percutaneous driveline. A plain film of the abdomen shows the left ventricular assist device (LVAD) in the left upper quadrant with kinking of the driveline. From Morris et al,¹¹⁹ with permission.

Considerations for non-cardiac surgery

In addition to the MCS team, consultation with an LVAD surgeon is recommended in planning the operative approach. Laceration of the driveline or violation of the pump pocket can have catastrophic consequences and is easily avoidable. Typically, a chest or abdominal X-ray will demonstrate the pump position (intrathoracic vs intra-abdominal) and course of the driveline, which can then be marked on the skin. Incisions and port placement in the case of laparoscopy can be adjusted accordingly. There are several cases that demonstrate the relative safety of operations in LVAD patients.^{45,46} Sterilized alligator clips to connect same-colored wires can be useful in the case of driveline injury resulting in pump stoppage. The connection of severed wires can be performed expeditiously and may avoid pump thrombosis and other serious complication before the pump or driveline can be safely replaced or definitively repaired. Any inadvertent injury or suspected injury to the VAD or one of its components should be immediately reported to the MCS team.

Pneumoperitoneum may have significant impact on venous return, RV performance, and subsequent device filling. Patients are at increased risk of PI or suction events during insufflation of the abdomen and communication between the surgeon, anesthesiologist, and MCS support personnel during this process may mitigate issues by way of fluid management and pump speed adjustment. Any left upper quadrant procedure such as splenectomy, or operations on the left and transverse colon, left kidney, tail of pancreas, diaphragm, left lung, or thoracic aorta should be performed cautiously with knowledge of the inflow cannula location (Figure 1).

Anesthesia considerations

Anesthesia management of LVAD patients undergoing surgery for non-LVAD-related emergencies requires specialized and continuous monitoring of the patient and device. Most important is continuous blood pressure monitoring with an arterial line. The ISHLT guidelines for MCS anesthesia during the device implant recommend a large bore IV, pulmonary artery (PA) catheter, and intraoperative TEE.¹⁷ While these are specific to LVAD implants, they are reasonable recommendations to consider for urgent/emergent non-cardiac operations as well, as they will aid in optimization of RV performance and LVAD function intraoperatively. In addition, patients should be managed whenever possible by a cardiac anesthesiologist experienced with LVADs. Care should be taken to avoid conditions (e.g., hypoxia, acidosis) that result in increased pulmonary vascular resistance, which can dramatically alter RV function, LV filling, and subsequently LVAD performance.⁴⁷ In addition, anesthetic agents with negative inotropic properties (e.g., propofol) should be avoided in patients with marginal or reduced RV function. An LVAD-trained specialist (typically an MCS coordinator, intensive care nurse, or perfusionist) should be present to monitor the pump. Resuscitation should focus on the patient, as in non-VAD cases, rather than the device. The pump diagnostics, however, can provide useful information regarding the patient's condition and alert experienced providers to specific physiologic conditions. Acute speed adjustments are rarely necessary in the absence of recurrent suction events, although decreased flow and pulsatility may indicate the need for volume replacement therapy or blood pressure management.

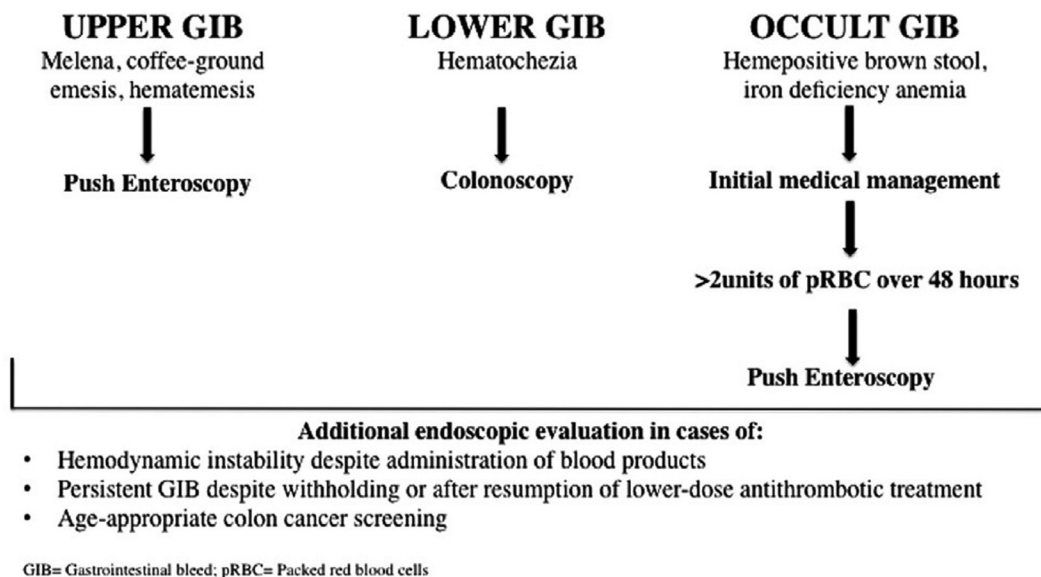


Figure 8 Algorithm for gastrointestinal bleeding in patients with a ventricular assist device (VAD). From Axelrad et al,⁵⁸ with permission.

Abdominal pain

A patient with an LVAD presenting with abdominal pain presents unique challenges in physical examination, imaging, resuscitation, and operative approach. Physical examination, in addition to careful history, provides the greatest tool in the proper diagnosis of abdominal pain. Patients may have tenderness around the driveline or the pump pocket that may mask or mimic other intra-abdominal processes. In addition, the presentation of a driveline or pump pocket infection (discussed below) may be mistaken for other diagnoses and must be considered in the differential. Similar approaches can be used for radiologic examination. However, windows from an abdominopelvic CT may be obscured by artifact from the pump. The usual relevant laboratory studies should be ordered and should not be significantly altered by the LVAD itself, with the exceptions of LDH and plasma-free hemoglobin (elevated) and haptoglobin (reduced).

In cases where urgent/emergent surgery is indicated, the multidisciplinary team should be familiar with VADs, including their operation and physiology. Case series have described successful intra-abdominal surgeries in patients with LVADs, including gastrectomy, abdominal exploration or bowel procedures, and laparoscopic cholecystectomy among others.^{45,48,49} Given the risk of bacteremia in this setting, ISHLT guidelines recommend antibiotic prophylaxis to prevent VAD endocarditis.¹⁷

Bleeding complications

Non-surgical bleeding is a common cause of morbidity in patients supported with continuous-flow LVADs. Among HeartMate II recipients, bleeding requiring transfusion, hospitalization, reoperation or death occurred in 19%-40% of patients.⁵⁰ Similar bleeding rates are reported for the HeartWare HVAD and HeartMate 3 devices.^{13,51} The

most common sources of bleeding include gastrointestinal and nasal, although intracranial and intrathoracic bleeding may also occur.^{50,52,53}

Platelet dysfunction, lysis of the von Willebrand polymer, and RV dysfunction with hepatic congestion all contribute to bleeding complications for the duration of VAD support.⁵⁴⁻⁵⁶ To reduce the risk of pump thrombosis and thromboembolic complications, patients with CF LVADs are prescribed dual anti-coagulant and anti-platelet therapy. The event rate of bleeding in these patients, however, far exceeds those observed in patients anti-coagulated for other reasons.⁵³

GI bleeding occurs in approximately 27% of patients with CF LVADs.^{6,57} The most common source of GI bleeding in these patients is arteriovenous malformations in either the stomach or duodenum.⁵⁷ A putative mechanism of GI angiodysplasia is gut hypoperfusion in the setting of decreased pulse pressure leading to dilation of the submucosal venous plexus and neovascularization. Altered angiogenesis may also contribute. Other common sources of GI bleeding include gastritis and peptic ulcer disease. Initial endoscopy and colonoscopy are recommended to identify a potentially treatable source of GI bleeding. However, the diagnostic yield of these procedures may be lower because many patients have a small bowel source of bleeding.⁵⁸ If bleeding is not identified, push enteroscopy or other methods of evaluating the small bowel are recommended.^{57,58} A suggested algorithm has recently been published that advocates push enteroscopy and colonoscopy as first-line investigations for upper and lower GI bleeding, respectively (Figure 8).⁵⁸ Algorithms such as these need to be tested to improve quality of care and reduce costs for patients.

The management of symptomatic GI bleeding begins with an assessment of hemodynamic stability together with resuscitative measures, including the transfusion of packed red blood cells and platelets as needed. In BTT patients, the transfusion of leucocyte depleted blood is preferable to reduce the risk of allosensitization. However, caution is

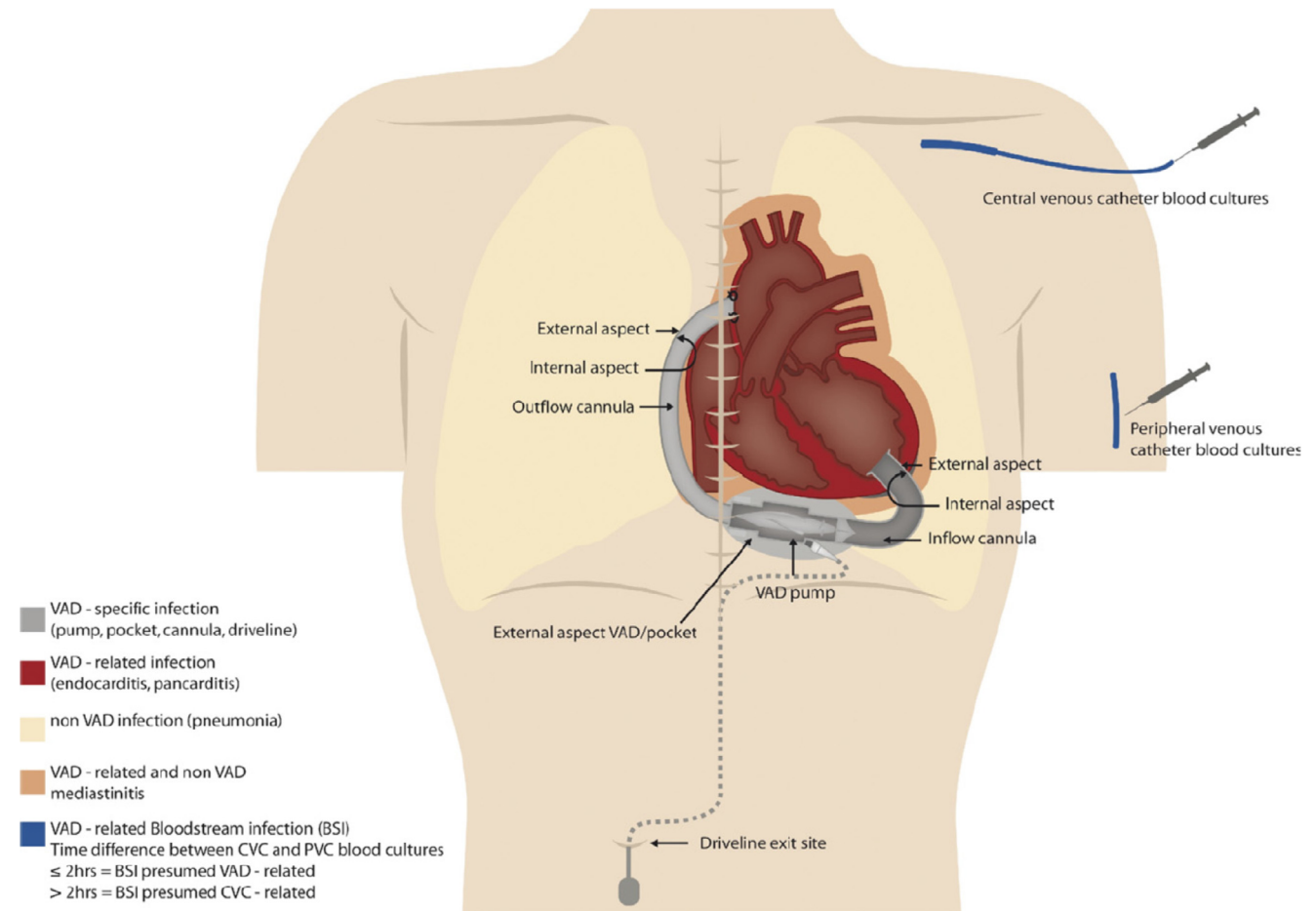


Figure 9 Standardization of infections in patients with ventricular assist devices (VADs). Illustration of VAD-specific, VAD-related, and non-VAD infections. BSI, bloodstream infection; CVC, central venous catheter; PVC, peripheral vascular catheter. From Hannan et al,⁷⁷ with permission.

advised as blood product resuscitation can increase PA pressures and worsen RV function. Anti-coagulation and anti-platelet agents are commonly withheld. Interruption of these therapies should be discussed with the patient's LVAD team, and reversal may be required. Proton pump inhibitor therapy may be initiated. The added benefit of octreotide and thalidomide in patients with angiodysplastic lesions has not been demonstrated, although some programs have incorporated these agents into their management strategy.^{59–63} Multidisciplinary care involving interventional gastroenterology and radiology is recommended.

Epistaxis is the second most common bleeding complication in patients supported with LVADs.⁵³ Initial management entails topical vasoconstriction, cautery, and nasal packing/tamponade at the bleeding site if it can be identified. Invasive intervention including embolization may be required to stop bleeding and supportive transfusion with blood products may be indicated. Early involvement of otolaryngology is advisable.

Stroke

Despite improvements in device design, cerebrovascular complications remain one of the more common adverse

events experienced by patients with LVADs.^{64,65} Patients with LVADs have a higher risk for stroke and intracranial bleeding, so first responders should be aware of neurological symptoms and perform a thorough history and physical assessment. The most devastating neurological events are ischemic (thromboembolic) and hemorrhagic strokes. Current research including that from the INTERMACS registry indicates that the incidence of stroke is approximately 10% per year in patients with LVADs, and these events significantly increase mortality.^{5,66} Timing of the events is variable; the highest risk occurs both in the early post-operative period, as well as 9-12 months after implantation.^{5,67} Despite a clear survival benefit favoring LVAD placement, strokes occur more than twice as frequently in patients with end-stage HF managed with mechanical support compared with those treated with optimal medical management.⁶⁸

As LVAD use for DT increases, the overall number of strokes related to MCS is likely to increase as well because of the longer duration of therapy and the greater numbers of at-risk individuals. Stroke risk following LVAD placement is increased by a number of factors, including (1) patient factors: age, baseline HF severity, history of diabetes, hypertension, prior stroke, hypercoagulable state, and female gender; (2) perioperative factors: use of aortic cross clamping with cardioplegic arrest; and (3) post-operative

factors: duration of mechanical support, infection, high or low INR, and higher systolic blood pressure at the time of discharge after the LVAD placement.^{69–72}

If an acute neurologic deficit develops in a patient with an LVAD, ISHLT guidelines recommend prompt CT of the head with angiography of the head and neck, as well as neurology consultation.¹⁷ LVAD parameters should be reviewed for any signs of device malfunction or thrombosis. Hospitals without MCS programs should urgently discuss the clinical situation with the patient's LVAD specialist(s) to review their management and determine if an urgent transfer is warranted. In hemorrhagic strokes, the discontinuation or reversal of anti-coagulation is recommended. In patients on warfarin, rapid reversal of anti-coagulation should be used to reduce the INR to <1.5.⁷³ Prothrombin complex concentrate may be chosen over fresh frozen plasma because of its ability to more rapidly lower the INR and also because of the risk of volume overload with fresh frozen plasma.^{74,75} The timing surrounding resumption of anti-coagulation and anti-platelet therapy should be discussed in consultation with neurology and neurosurgery.

In patients with ischemic strokes without evidence of hemorrhage, selective use of systemic or intra-arterial thrombolytic agents or an interventional neuroradiologic procedure (e.g., endovascular thrombectomy, retrievable stent) may be considered. However, in the absence of prospective data, neither is routinely recommended. Case reports of patients with thromboembolic stroke complicated by VAD thrombosis have demonstrated the safe and successful use of systemic thrombolysis.⁷⁶

Infection/Sepsis

The 2011 ISHLT working group standardized the definitions of LVAD infections and classified them into VAD-specific, VAD-related, and non-VAD-related (Figure 9).⁷⁷ Non-VAD-related infections are those not affected by the presence of the VAD but occur in a patient with a VAD, such as urinary tract infection or pneumonia. These infections are treated in the usual fashion. VAD-related infections refer to infections not involving the VAD itself but infections that can have different characteristics or implications and management when present in a VAD patient. These include infective endocarditis, bacteremia, and mediastinitis.⁷⁸ VAD-specific infections involve the driveline, pocket, pump, and/or cannula. Nonetheless, infections, both VAD-related and VAD-unrelated, are common complications of MCS and have serious implications for patients, especially for those implanted as DT. The prevention, diagnosis, and treatment of infections are critical to proper VAD management.

In the HeartMate II BTT trial, 19 of 133 patients (14%) developed percutaneous lead infections.⁴ In the follow-up DT trial, 35% of patients undergoing HeartMate II implant developed LVAD-related infections (0.48 events per patient-year).^{11,79} In another large HeartMate II series, the odds of developing an infection

increased approximately 4% for each additional month of LVAD support.⁸⁰ Sepsis significantly decreases survival in patients with both continuous and pulsatile-flow devices.⁸¹ While infection rates have significantly decreased, they remain a major cause of morbidity and mortality in patients supported by MCS.

Risk factors for the development of a VAD infection include driveline trauma, continuous pump movement because of poor anchoring, and malnutrition.⁸² Device placement (e.g., pre-peritoneal), rigid or thicker driveline, larger pocket size, and duration of support have also been linked to infection, particularly late risk.⁸³ Studies assessing body mass index are inconclusive in implicating a role for obesity in infectious complications.⁸⁴ In translational work, susceptibility to infection in patients with durable LVADs has been linked to defects in cellular and humoral immune responses⁸³ and increased level of proinflammatory cytokines.^{85,86}

Many studies have estimated the incidence of VAD infections and related outcomes. However, the lack of standardized definitions and single-center experiences led to significant variability in incident reporting. Standardizing classification of VAD infections can lead to more accurate data and the ability to study successful treatment options and algorithms.

Driveline infection

Infection of the percutaneous driveline can manifest in 3 different stages (Figure 10). Stage 1 is erythema involving the superficial aspect of skin without purulent drainage or systemic signs of infection. Stage 2 is superficial infection or cellulitis. There may be purulent drainage from the incision site or spreading cellulitis with erythema, warmth, and tenderness. Stage 3 is a deep infection that encompasses all the above and involves the deep soft tissue layers including both fascia and muscle. In addition, wound dehiscence and abscess formation may be present. Systemic signs of infection such as fever and leukocytosis suggest a stage 2 or 3 infection.

Pocket infection

Pocket infections refer to infection of the space housing the pump. First-generation pumps (e.g., HeartMate XVE) required larger pocket space and were often placed intra-abdominally. The newer CF devices are routinely placed in the intrathoracic (HeartWare HVAD, HeartMate 3) or pre-peritoneal (HeartMate II) space, and some do not require a pocket. Diagnosis of pump pocket infection requires systemic signs that may be very subtle, in addition to positive cultures from the pocket space and evidence of infection in the pocket area such as an abscess. CT scan and/or ultrasound should be used to assess for fluid collections around the device and guide needle aspiration. In addition, leukocyte scintigraphy and SPECT/CT have been shown to be more sensitive for early diagnosis of driveline and pump pocket infections.⁸⁷

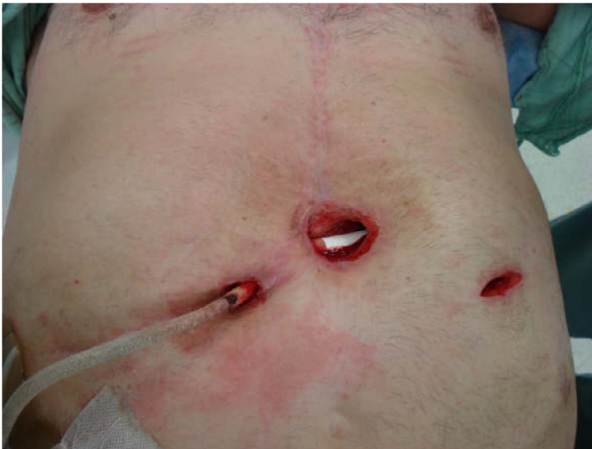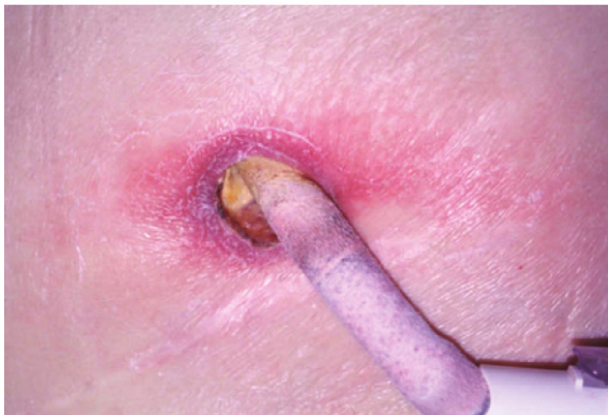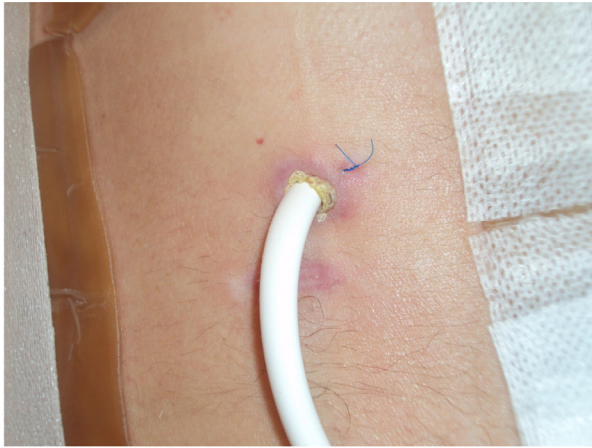


Figure 10 Stages of left ventricular assist device (LVAD) driveline infection. Top panel: stage 1 is shown as erythema involving the superficial aspect of skin without purulent drainage. Middle panel: stage 2 is represented by superficial infection and cellulitis with surrounding warmth and erythema. Bottom panel: stage 3 is a deep tissue infection that involves soft tissue layers including fascia and muscle requiring extensive surgical debridement.

Pump and/or cannula infections

The ISHLT working group proposed diagnostic criteria for pump and/or cannula infection based on modified Duke criteria.⁷⁷ Clinical diagnosis requires 2 major criteria, 1 major and 3 minor criteria, or 4 minor criteria (Table 6). Early diagnosis is key and is primarily made through

clinical signs and symptoms, microbiological workup, and imaging to assess for possible involvement of the pump pocket and extension into deeper tissues. The presence of positive blood cultures is important as systemic manifestations, such as fever, leukocytosis, or systemic inflammatory response syndrome criteria, may be present in only 50% of patients with an infection.⁸⁸ If a driveline or pump pocket infection is suspected, tagged white blood cell scan or positron emission tomography-CT is useful in discerning both the presence and extent of infection.^{87,89–92} Positron emission tomography-CT imaging with F-18 fluorodeoxyglucose may allow for earlier detection of the LVAD infection and its extent, as well as for evaluating response to therapy.^{86,88}

Bloodstream infection

Bloodstream infection can occur in up to 30% of patients with LVADs, typically within the first 3 months post-implant, and is associated with stroke and increased mortality.^{67,93} Risk factors include increased body mass index, older age, prior cardiac surgery, chronic kidney disease, and frailty. While bloodstream infection may be related to the driveline, pocket, or pump, other sources (e.g., cardiovascular implantable electronic devices, native or prosthetic valve endocarditis) should be investigated and managed per guidelines. Ambulatory patients with LVADs are also at a risk for community-acquired infections such as pneumonia or urinary tract infection that can lead to bacteremia and do not require prolonged antimicrobial therapy. Consultation with an infectious disease specialist with expertise in device-related infections should be obtained if available.

The most common pathogens leading to device-related infection include *Staphylococcus*, *Enterococcus* and *Pseudomonas* species. Fungal infections are rare,⁹⁴ and most are caused by *Candida* species, with a few case reports of *Aspergillus* and other molds. Risk factors include the use of total parenteral nutrition. The routine use of anti-fungal prophylaxis does not decrease the risk of fungal infection in VAD patients.⁹⁵

Guidelines for the management of LVAD-associated infections are based on the type and extent of the infection.⁹⁴ Patients with documented *device-related infection* should be treated aggressively with targeted antibiotic therapy for 4–6 weeks and surgical intervention/debridement as needed. Central lines and ICD generators and leads should be removed according to current guidelines,^{96,97} with the recognition that it is generally not possible to remove all intravascular equipment (e.g., the LVAD itself). A multidisciplinary team that includes VAD and infectious disease specialists is ideal to individualize patient-care decisions.

V. VAD-specific emergencies

Pump thrombosis

Acute thrombosis can occur with any of the approved devices.^{6,13,98} Lower pump speed, reduced anti-

Table 5 Summary Approach to the Patient With an LVAD and Penetrating Trauma

Hemodynamic stability and VAD pump functionality	Management
Stable/functional pump	Obtain additional relevant imaging and admit to a VAD-capable ICU or step-down unit based on clinical judgment.
Stable/non-functional pump	Attempt to repower device, checking equipment and connections, and replacing components. If unsuccessful, the device will likely require replacement. Obtain other relevant imaging and admit to a VAD-capable ICU. Monitor closely for hemodynamic decline with the placement of a PA catheter while planning urgent or semi-urgent pump replacement.
Unstable/functional pump	Proceed to the OR based on clinical judgment, with appropriate monitoring, cardiac anesthesia with VAD expertise, intraoperative TEE, appropriate number of blood products, and perfusion or other VAD-trained staff.
Unstable/non-functional pump	Assess the patient for salvageability and attempt to restart the pump. Monitor with an echocardiogram and PA catheter if possible and consider inotropic/vasopressor agents. IABP or ECMO may be required to provide circulatory support. Secondary assessment for stability made after restoring circulation followed by the decision to proceed to CT.
Unsalvageable	Emotional support and palliative care

CT, computerized tomography; ECMO, extracorporeal membrane oxygenation; IABP, intra-aortic balloon pump; ICU, intensive care unit; LVAD, left ventricular assist device; OR, operating room; PA, pulmonary artery; TEE, transesophageal echocardiogram; VAD, ventricular assist device.

Table 6 ISHLT Working Group Diagnostic Criteria for Pump and Cannula Infections

Major criteria	<ol style="list-style-type: none"> 1. Recovery of an indistinguishable organism (similar in terms of genus, species and antimicrobial susceptibility pattern) from 2 or more sets of peripheral blood cultures obtained over a 4-week period, with no other focus of infection 2. Blood cultures from a central venous catheter turning positive ≤ 2 hours after blood cultures drawn from peripheral blood 3. Echocardiogram showing oscillating mass adherent to the VAD
Minor criteria	<ol style="list-style-type: none"> 1. Fever $\geq 38^{\circ}\text{C}$ 2. Vascular phenomena such as major arterial emboli, septic pulmonary infarcts, mycotic aneurysm, intracranial hemorrhage, conjunctival hemorrhage, or Janeway lesions 3. Immunological phenomena such as glomerulonephritis, Osler nodes, or Roth spots 4. Microbiological evidence such as positive blood cultures that do not meet the criteria as noted above.^{96,120}

VAD, ventricular assist device.

coagulation targets, and poorly controlled blood pressure can increase thrombosis risk,^{98,99} whereas optimized surgical and medical management has been shown to reduce this complication.¹⁰⁰ Pump thrombosis is a catastrophic VAD emergency necessitating prompt diagnosis and treatment. One should suspect pump thrombosis with lasting increases in pump power by $>50\%$ accompanied by elevated, inaccurate flow estimates, as well as hemolysis manifested as an LDH elevation. However, power elevation may be absent if the thrombus is not in the pump itself, so elevated LDH without any other explanation is concerning. Fibrin deposition on the inflow contact bearing or along one of the rotor's blood flow channels can create drag, necessitating power increases to maintain pump speed. Internal pump thrombosis may disrupt laminar blood flow through the device. The resulting turbulent flow increases shear stress leading to hemolysis that manifests clinically as hemoglobinuria with dark, "tea-colored" or frankly bloody urine. Urinalysis may be positive for blood without red blood cells. Pigment nephropathy is a medical emergency that results in acute kidney injury and oliguria if not corrected early. Hemolysis may be detected

by elevations in serum LDH (>600 mg/dl or 2.5 times baseline depending on the assay used), elevated free hemoglobin (>40 mg/dl), increased total and indirect bilirubin or reduced haptoglobin levels.¹⁰¹ HF symptoms may be present, although non-occlusive thrombi can result in significant hemolysis in the absence of hemodynamic instability. In extreme cases, patients may exhibit symptoms and signs of congestion and systemic hypoperfusion indicative of low cardiac output, even though the pump displays a normal or elevated pump flow, as well as shock and death.

When pump thrombosis is suspected or diagnosed, patients should be transported as soon as possible to the nearest VAD center where pump exchange or lysis can be performed if urgently required.¹⁰² Proper management begins with hospitalization and the administration of adequate levels of systemic anti-coagulation, usually with unfractionated heparin or a direct thrombin inhibitor. Admission to an intensive care unit (ICU), inotropic support and diuretic therapy may be appropriate during a period of watchful waiting to determine if the situation reverses. Published reports of successful treatment with heparin or bivalirudin have led some

to consider these interventions before considering surgery.¹⁰³ Tissue plasminogen activator has been used with mixed results,^{104,105} and we recommend against using lytic agents as first- or second-line therapy. The administration of tissue plasminogen activator should only be considered after contacting the implanting center and obtaining a head CT to exclude sub-acute stroke with the risk of hemorrhagic conversion. Although medical treatment with anti-coagulant agents or thrombolytic therapy can lead to clot resolution, the rate of recurrence is high,¹⁰⁶ as is the subsequent risk of stroke and death.¹⁰⁷

If the situation does not resolve with conservative measures, surgical pump exchange is indicated, assuming the patient is a suitable surgical candidate, and urgent transplantation is not feasible. Although patient survival following pump exchange is less than that for de novo implants, the 1-year survival rates exceed 65%.¹⁰⁸ Complications such as pump thrombosis can affect patients' listing status for transplant. Therefore, it is crucial that the implanting center be made immediately aware of them.

Pump stoppage or failure, driveline trauma

A little more than 3.5% of all deaths on CF LVAD support are attributed to device malfunction.¹⁰⁸ Failures can occur in the internal or external portion of the driveline, patient cable, pump controller, or with external power. Rarely has there been an issue with the rotor or, in the case of the HeartMate II, the contact bearings. In 2012, the Food and Drug Administration issued a recall of the HeartMate II after it was recognized that the outflow bend relief, a section of polytetrafluoroethylene tubing designed to prevent kinking, could detach from the pump housing and migrate cephalad.¹⁰⁹ Such detachments could lead to outflow obstruction, hemolysis or HF symptoms. Rarely, the sharp metal collar could directly damage the outflow graft and cause bleeding. Such detachments were visible with chest or abdominal radiographs that were used to screen asymptomatic individuals. The use of a new locking collar has eliminated this problem. More recently, the Food and Drug Administration issued an advisory regarding the HeartMate 3 and risk of outflow graft twist with an occurrence rate of up to 1.6%.¹¹⁰ This slow rotation occurs over a prolonged period of time, leads to mechanical obstruction to flow, and may cause stasis and thrombosis. Diagnosis can be made by CT angiography, and surgical correction (graft or complete pump exchange) or an urgent transplant is required.

Pump stoppage occurs when there is a complete loss of power to the pump. This can arise because of the depletion of battery power, disconnection of both power leads, or disconnection of the percutaneous lead from the system controller. The alarm varies depending on the equipment. For the HeartWare device, an alarm accompanies a red triangle on the pocket controller. If all power sources are completely removed, the screen will go black, but the internal battery will power the audible alarm. The HeartMate II and 3 have an internal battery source that will power the pump for 15 minutes and have a "red heart" alarm. Pump

stoppage is an unstable situation that leads to severe regurgitation of blood from the aorta into the LV because the pump does not contain valves to prevent flow reversal. Even patients with some cardiac reserve will present with symptoms of acute HF. The pump will remain silent upon chest auscultation. Treatment requires restoring power to the pump even though doing so in patients with sub-therapeutic anti-coagulation risks thromboembolism and stroke. If the patient is in cardiogenic shock, vasopressors along with inotropes may be needed to support diminished heart function during emergency transport. If available, venous-arterial extracorporeal membrane oxygenation may also be considered in this setting.

Both acute and chronic driveline trauma may result in pump stoppages.^{111,112} Partial percutaneous lead disruption may be amenable to repair by soldering together disrupted wires. Complete transection will require urgent surgical pump replacement. Repetitive flexing and bending of the percutaneous lead may abrade the insulation wrapping one or more of the 6 individual wires in the HeartMate II, allowing them to make contact with the protective metal shielding.¹¹³ The ensuing "short-to-shield" arises when patients are connected to the power module through a grounded cable. These short circuits may temporarily or permanently stop the pump from rotating and are accompanied by a constant alarm. Acute management requires using an ungrounded cable or placing patients on batteries only, although this leads to a less stable long-term situation given the loss of redundancy should there be further damage to the percutaneous lead. Temporary or more durable repairs can sometimes be performed by an industry engineer specific to each device depending on the location of the fracture (internal vs external).⁴⁴ Device exchange may be required.

The "Electric Fault" in the HVAD pump is due to biologic matter within the driveline contact with the controller or driveline damage. The device manufacturer recommends against exchanging the controller in this situation, as the pump, which is running on a single stator, may not restart if stopped during the exchange. Rather, controller log files should be downloaded by a VAD clinician and sent to the company for review.

Heart failure with a left ventricular assist device

Patients implanted with CF LVADs may present for emergency care of acute HF. Most often they demonstrate sub-acute progression of symptoms, but less frequently, sudden decompensation requiring emergent intervention can occur. Several potential factors can reduce LVAD flow leading to congestion and a low cardiac output state.¹¹⁴

Inadequate left ventricular decompression

Inadequate decompression of the LV can lead to HF in patients with an LVAD. Causative factors include (1) sub-optimal pump speed setting; (2) increased afterload; (3) obstruction to blood flow; (4) thrombosis of the pump impeller; or (5) aortic insufficiency. When the LVAD fails to

adequately decrease LV volumes, imaging may reveal LV dilation, functional mitral valve regurgitation, and frequent aortic valve opening. Patients often experience clinical symptoms of fatigue and dyspnea and may have signs of congestion on exam. Sub-optimal pump speed setting and increased afterload may result in a more insidious presentation of HF and will respond to speed adjustments, diuresis, and anti-hypertensive therapies. Rarely, patients will present with acute HF or shock prompting urgent hospitalization.

Increased afterload is most frequently caused by poorly controlled blood pressure, which increases the pressure differential against which the LVAD must work and, thus, results in reduced pump output. The monitor will display decreased power consumption and low-flow estimates, while the metrics of pulsatility through the LVAD may be increased because of poor flow during diastole. Extreme blood pressure increases can obliterate flow through the device, increasing the risk of cerebrovascular accidents and pump thrombosis. The keys to prevention are meticulous blood pressure control through patient adherence to anti-hypertensive therapy and, in some cases, home blood pressure monitoring.

Kinks or obstruction to the inflow (sudden or gradual) or outflow cannulae (gradual) can lead to HF with low power consumption and estimated flow displayed on the LVAD controller or monitor. Inflow cannula obstruction reduces pre-load to the LVAD and may occur gradually as a result of pannus formation or the misalignment of the cannula because of LV remodeling or orientation of the pump pocket (i.e., changing abdominal girth). This can occur abruptly as with the development of inflow wedge thrombus usually from a clot originating within a left-sided cardiac chamber. Abrupt cannula obstruction may present as a medical emergency with sudden HF, syncope, or shock.^{115,116} When the source of HF is inflow or outflow cannula obstruction, surgical intervention is often required. The presence, location, and hemodynamic significance of cannula obstruction can typically be investigated with use of CT angiography and right heart catheterization. Occasionally, left heart catheterization with ventriculography, retrograde contrast injection into the outflow graft, or pressure wire assessment of gradient is needed.

Right ventricular failure

RV failure is a common cause for hospitalization among VAD patients and is often associated with worsening renal function. Early post-operative causes include pre-existing RV disease, perioperative RV injury, excessive volume resuscitation, or tamponade because of mediastinal hematoma. In the sub-acute and chronic settings, RV dysfunction can be due to ventricular arrhythmias, pulmonary embolism (if INR is sub-therapeutic), persistent pulmonary hypertension, and new or worsening tricuspid regurgitation.¹¹⁴ Excessive pump speed and flow can also overwhelm an already compromised right ventricle at any time following LVAD implant. RV failure can lead to hemodynamic deterioration, ICD shocks, and even cardiac arrest with VT/VF caused by impaired filling and inadequate LVAD flows. In all low-flow cases, an echocardiogram should be urgently

obtained to assess the RV and LV dimensions and filling and rule out tamponade (Table 3).¹⁷

For patients with sub-acute or chronic right HF, medical management includes diuretic therapy and positive inotropic support, typically with milrinone. If pulmonary hypertension is playing a role, pulmonary vasodilator therapy with phosphodiesterase-5 inhibitors can be considered, but safety and efficacy are unproven.¹¹⁷ The use of parenteral vasoactive and diuretic therapy should be guided by invasive hemodynamics measured with a PA catheter. Rarely percutaneous right ventricular support may be needed.

Summary and future directions

A growing number of adults with end-stage HF are living in the community with MCS as BTT or DT. These VAD patients may have urgent or emergent medical needs requiring hospital-level care. This consensus document by the Heart Failure Society of America, Society for Academic Emergency Medicine, and ISHLT aims to provide front-line clinicians with information needed to understand the basics of continuous-flow pumps and how to handle patients and their equipment in emergency situations. More detailed information on specific devices is available online at manufacturers' websites or by contacting their clinical specialists. A list of VAD implanting centers in the US and Canada can also be found online at www.uab.edu/medicine/intermacs/enroll/currently-enrolled. Future studies will focus on the management of device settings, fluid resuscitation, and anti-coagulation around non-cardiac surgery and trauma. The extrapolation of these emergency management guidelines to a small, but emerging population of pediatric patients living at home with VADs will also need to be explored. Finally, the presence of VAD emergencies and complications will take on even greater importance as VAD patients are projected to have longer waits for heart transplantation under the revised United Network of Organ Sharing heart allocation system.¹¹⁸

Disclosure statement

Abbott provided institutional research support (to M.M.G.). M.C. is a coinvestigator with the HeartMate 3 IDE Clinical Study and Continued Access Protocol. B.C.H. is a consultant to Novartis and AstraZeneca and serves on the advisory board. S.P.P. is a consultant to Thoratec/St. Jude/Abbott and CareDx. K.B.S. is a consultant to Medtronic. E.M.D., C.E.D., T.E., E.H., J.L.M., J.V., and M.B. have no conflicts of interest to disclose.

References

1. Stewart GC, Givertz MM. Mechanical circulatory support for advanced heart failure: patients and technology in evolution. *Circulation* 2012;125:1304-15.
2. Miller LW, Guglin M. Patient selection for ventricular assist devices: a moving target. *J Am Coll Cardiol* 2013;61:1209-21.
3. Ammirati E, Oliva F, Cannata A, et al. Current indications for heart transplantation and left ventricular assist device: a practical point of view. *Eur J Intern Med* 2014;25:422-9.

4. Miller LW, Pagani FD, Russell SD, et al. Use of a continuous-flow device in patients awaiting heart transplantation. *N Engl J Med* 2007;357:885-96.
5. Kirklin JK, Pagani FD, Kormos RL, et al. Eighth annual INTERMACS report: special focus on framing the impact of adverse events. *J Heart Lung Transplant* 2017;36:1080-6.
6. Mehra MR, Goldstein DJ, Uriel N, et al. Two-year outcomes with a magnetically levitated cardiac pump in heart failure. *N Engl J Med* 2018;378:1386-95.
7. Stevenson LW. Left ventricular assist devices as destination therapy for end-stage heart failure. *Curr Treat Options Cardiovasc Med* 2004;6:471-9.
8. Smith LA, Yarboro LT, Kennedy JL. Left ventricular assist device implantation strategies and outcomes. *J Thorac Dis* 2015;7:2088-96.
9. Stevenson LW, Rose EA. Left ventricular assist devices: bridges to transplantation, recovery, and destination for whom? *Circulation* 2003;108:3059-63.
10. Caccamo M, Eckman P, John R. Current state of ventricular assist devices. *Curr Heart Fail Rep* 2011;8:91-8.
11. Slaughter MS, Rogers JG, Milano CA, et al. Advanced heart failure treated with continuous-flow left ventricular assist device. *N Engl J Med* 2009;361:2241-51.
12. Mehra MR, Naka Y, Uriel N, et al. A fully magnetically levitated circulatory pump for advanced heart failure. *N Engl J Med* 2017;376:440-50.
13. Uriel N, Colombo PC, Cleveland JC, et al. Hemocompatibility-related outcomes in the MOMENTUM 3 trial at 6 months: a randomized controlled study of a fully magnetically levitated pump in advanced heart failure. *Circulation* 2017;135:2003-12.
14. Lanier GM, Orlanes K, Hayashi Y, et al. Validity and reliability of a novel slow cuff-deflation system for noninvasive blood pressure monitoring in patients with continuous-flow left ventricular assist device. *Circ Heart Fail* 2013;6:1005-12.
15. Myers TJ, Bolmers M, Gregoric ID, Kar B, Frazier OH. Assessment of arterial blood pressure during support with an axial flow left ventricular assist device. *J Heart Lung Transplant* 2009;28:423-7.
16. Castagna F, Stöhr EJ, Pinsino A, et al. The unique blood pressures and pulsatility of LVAD patients: current challenges and future opportunities. *Curr Hypertens Rep* 2017;19:85.
17. Feldman D, Pamboukian SV, Teuteberg JJ, et al. The 2013 International Society for Heart and Lung Transplantation Guidelines for mechanical circulatory support: executive summary. *J Heart Lung Transplant* 2013;32:157-87.
18. Oleyar M, Stone M, Neustein SM. Perioperative management of a patient with a nonpulsatile left ventricular-assist device presenting for noncardiac surgery. *J Cardiothorac Vasc Anesth* 2010;24:820-3.
19. Netuka I, Ivák P, Tučanová Z, et al. Evaluation of low-intensity anticoagulation with a fully magnetically levitated centrifugal-flow circulatory pump—the MAGENTUM 1 study. *J Heart Lung Transplant* 2018;37:579-86.
20. Van de Bussche TJ, Edwards LG, Elliott T, Harton S, Rivard D, Wolfe AC Jr. Regionalized approach to emergency medical services training for the care of patients with mechanical assist devices. *Prog Transplant* 2010;20:129-32. quiz 133.
21. Peberdy MA, Gluck JA, Ornato JP, et al. Cardiopulmonary resuscitation in adults and children with mechanical circulatory support: a scientific statement from the American Heart Association. *Circulation* 2017;135:e1115-34.
22. Schweiger M, Dave H, Lemme F, Romanchenko O, Hofmann M, Hübler M. Ventricular assist devices: initial orientation. *J Thorac Dis* 2013;5:567-71.
23. Garg S, Ayers CR, Fitzsimmons C, et al. In-hospital cardiopulmonary arrests in patients with left ventricular assist devices. *J Card Fail* 2014;20:899-904.
24. Mavuure NT, Rodrigues JN. External cardiac compression during cardiopulmonary resuscitation of patients with left ventricular assist devices. *Interact Cardiovasc Thorac Surg* 2014;19:286-9.
25. Collins SP, Levy PD, Lindsell CJ, et al. The rationale for an acute heart failure syndromes clinical trials network. *J Card Fail* 2009;15:467-74.
26. Fried J, Garan AR, Shames S, et al. Aortic root thrombosis in patients supported with continuous-flow left ventricular assist devices. *J Heart Lung Transplant* 2018;37:1425-32.
27. Dunlay SM, Haas LR, Herrin J, et al. Use of post-acute care services and readmissions after left ventricular assist device implantation in privately insured patients. *J Card Fail* 2015;21:816-23.
28. Akhter SA, Badami A, Murray M, et al. Hospital readmissions after continuous-flow left ventricular assist device implantation: incidence, causes, and cost analysis. *Ann Thorac Surg* 2015;100:884-9.
29. Boudghène-Stambouli F, Boulé S, Goéminne C, et al. Clinical implications of left ventricular assist device implantation in patients with an implantable cardioverter-defibrillator. *J Interv Card Electrophysiol* 2014;39:177-84.
30. Garan AR, Yuzefpolskaya M, Colombo PC, et al. Ventricular arrhythmias and implantable cardioverter-defibrillator therapy in patients with continuous-flow left ventricular assist devices: need for primary prevention? *J Am Coll Cardiol* 2013;61:2542-50.
31. Cantillon DJ, Tarakji KG, Kumbhani DJ, Smedira NG, Starling RC, Wilkoff BL. Improved survival among ventricular assist device recipients with a concomitant implantable cardioverter-defibrillator. *Heart Rhythm* 2010;7:466-71.
32. Raasch H, Jensen BC, Chang PP, et al. Epidemiology, management, and outcomes of sustained ventricular arrhythmias after continuous-flow left ventricular assist device implantation. *Am Heart J* 2012;164:373-8.
33. Cantillon DJ, Saliba WI, Wazni OM, et al. Low cardiac output associated with ventricular tachyarrhythmias in continuous-flow LVAD recipients with a concomitant ICD (LoCo VT Study). *J Heart Lung Transplant* 2014;33:318-20.
34. Berg DD, Vaduganathan M, Upadhyay GA, Singh JP, Mehra MR, Stewart GC. Cardiac implantable electronic devices in patients with left ventricular assist systems. *J Am Coll Cardiol* 2018;71:1483-93.
35. Meng L, Tseng CH, Shivkumar K, Ajijola O. Efficacy of stellate ganglion blockade in managing electrical storm: a systematic review. *JACC Clin Electrophysiol* 2017;3:942-9.
36. Fasseas P, Kutalek SP, Kantharia BK. Prolonged sustained ventricular fibrillation without loss of consciousness in patients supported by a left ventricular assist device. *Cardiology* 2002;97:210-3.
37. Fasseas P, Kutalek SP, Samuels FL, Holmes EC, Samuels LE. Ventricular assist device support for management of sustained ventricular arrhythmias. *Tex Heart Inst J* 2002;29:33-6.
38. Tanna MS, Reyentovich A, Balsam LB, et al. Aortic root thrombus complicated by left main coronary artery occlusion visualized by 3D echocardiography in a patient with continuous-flow left ventricular assist device. *Echocardiography* 2017;34:306-10.
39. Spina R, Siriwardena M, Bart N, et al. Primary percutaneous coronary intervention for inferior ST-segment elevation myocardial infarction in a patient supported by the HeartWare left ventricular assist device. *Intern Med J* 2017;47:1068-71.
40. Bellavia D, Iacovoni A, Scardulla C, et al. Prediction of right ventricular failure after ventricular assist device implant: systematic review and meta-analysis of observational studies. *Eur J Heart Fail* 2017;19:926-46.
41. Dang NC, Topkara VK, Mercado M, et al. Right heart failure after left ventricular assist device implantation in patients with chronic congestive heart failure. *J Heart Lung Transplant* 2006;25:1-6.
42. Hussmann B, Lendemans S. Pre-hospital and early in-hospital management of severe injuries: changes and trends. *Injury* 2014;45(Suppl 3):S39-42.
43. ATLS Subcommittee, American College of Surgeons' Committee on Trauma, International ATLS working group. Advanced trauma life support (ATLS®): the ninth edition. *J Trauma Acute Care Surg* 2013;74:1363-6.
44. Stulak JM, Schettle S, Haglund N, et al. Percutaneous driveline fracture after implantation of the HeartMate II left ventricular assist device: how durable is driveline repair? *ASAIO J* 2017;63:542-5.
45. Morgan JA, Paone G, Neme HW, et al. Non-cardiac surgery in patients on long-term left ventricular assist device support. *J Heart Lung Transplant* 2012;31:757-63.

46. Webb ST, Patil V, Vuylsteke A. Anaesthesia for non-cardiac surgery in patient with Becker's muscular dystrophy supported with a left ventricular assist device. *Eur J Anaesthesiol* 2007;24:640-2.
47. Stone M, Hinchey J, Sattler C, Evans A. Trends in the management of patients with left ventricular assist devices presenting for noncardiac surgery: a 10-year institutional experience. *Semin Cardiothorac Vasc Anesth* 2016;20:197-204.
48. Nakamura Y, Toda K, Nakamura T, et al. Curative surgery for gastric cancer in a patient with an implantable left ventricular assist device. *J Artif Organs* 2017;20:170-3.
49. Suresh V, Bishawi M, Bryner B, et al. Outcomes of laparoscopic cholecystectomy in patients supported with a left ventricular assist device. *J Laparoendosc Adv Surg Tech A* 2019;29:441-4.
50. Nascimbene A, Neelamegham S, Frazier OH, Moake JL, Dong JF. Acquired von Willebrand syndrome associated with left ventricular assist device. *Blood* 2016;127:3133-41.
51. Aaronson KD, Slaughter MS, Miller LW, et al. Use of an intrapericardial, continuous-flow, centrifugal pump in patients awaiting heart transplantation. *Circulation* 2012;125:3191-200.
52. Crow S, John R, Boyle A, et al. Gastrointestinal bleeding rates in recipients of nonpulsatile and pulsatile left ventricular assist devices. *J Thorac Cardiovasc Surg* 2009;137:208-15.
53. Wever-Pinzo O, Selzman CH, Drakos SG, et al. Pulsatility and the risk of nonsurgical bleeding in patients supported with the continuous-flow left ventricular assist device HeartMate II. *Circ Heart Fail* 2013;6:517-26.
54. Uriel N, Pak SW, Jorde UP, et al. Acquired von Willebrand syndrome after continuous-flow mechanical device support contributes to a high prevalence of bleeding during long-term support and at the time of transplantation. *J Am Coll Cardiol* 2010;56:1207-13.
55. Crow S, Chen D, Milano C, et al. Acquired von Willebrand syndrome in continuous-flow ventricular assist device recipients. *Ann Thorac Surg* 2010;90:1263-9. discussion 1269.
56. Sparrow CT, Nassif ME, Raymer DS, Novak E, LaRue SJ, Schilling JD. Pre-operative right ventricular dysfunction is associated with gastrointestinal bleeding in patients supported with continuous-flow left ventricular assist devices. *JACC Heart Fail* 2015;3:956-64.
57. Draper KV, Huang RJ, Gerson LB. GI bleeding in patients with continuous-flow left ventricular assist devices: a systematic review and meta-analysis. *Gastrointest Endosc* 2014;80:435-46.e1.
58. Axelrad JE, Pinsino A, Trinh PN, et al. Limited usefulness of endoscopic evaluation in patients with continuous-flow left ventricular assist devices and gastrointestinal bleeding. *J Heart Lung Transplant* 2018;37:723-32.
59. Aggarwal A, Pant R, Kumar S, et al. Incidence and management of gastrointestinal bleeding with continuous flow assist devices. *Ann Thorac Surg* 2012;93:1534-40.
60. Demirozu ZT, Radovancevic R, Hochman LF, et al. Arteriovenous malformation and gastrointestinal bleeding in patients with the HeartMate II left ventricular assist device. *J Heart Lung Transplant* 2011;30:849-53.
61. Hayes HM, Dembo LG, Larbalestier R, O'Driscoll G. Management options to treat gastrointestinal bleeding in patients supported on rotary left ventricular assist devices: a single-center experience. *Artif Organs* 2010;34:703-6.
62. Draper K, Kale P, Martin B, Cordero K, Ha R, Banerjee D. Thalidomide for treatment of gastrointestinal angiodysplasia in patients with left ventricular assist devices: case series and treatment protocol. *J Heart Lung Transplant* 2015;34:132-4.
63. Ray R, Kale PP, Ha R, Banerjee D. Treatment of left ventricular assist device-associated arteriovenous malformations with thalidomide. *ASAIO J* 2014;60:482-3.
64. Acharya D, Loyaga-Rendon R, Morgan CJ, et al. INTERMACS analysis of stroke during support with continuous-flow left ventricular assist devices: risk factors and outcomes. *JACC Heart Fail* 2017;5:703-11.
65. Parikh NS, Cool J, Karas MG, Boehme AK, Kamel H. Stroke risk and mortality in patients with ventricular assist devices. *Stroke* 2016;47:2702-6.
66. Harvey L, Holley C, Roy SS, et al. Stroke after left ventricular assist device implantation: outcomes in the continuous-flow era. *Ann Thorac Surg* 2015;100:535-41.
67. Frontera JA, Starling R, Cho SM, et al. Risk factors, mortality, and timing of ischemic and hemorrhagic stroke with left ventricular assist devices. *J Heart Lung Transplant* 2017;36:673-83.
68. Starling RC, Estep JD, Horstmannshof DA, et al. Risk assessment and comparative effectiveness of left ventricular assist device and medical management in ambulatory heart failure patients: the ROADMAP Study 2-year results. *JACC Heart Fail* 2017;5:518-27.
69. Morris AA, Pekarek A, Wittersheim K, et al. Gender differences in the risk of stroke during support with continuous-flow left ventricular assist device. *J Heart Lung Transplant* 2015;34:1570-7.
70. Nassif ME, Tibrewala A, Raymer DS, et al. Systolic blood pressure on discharge after left ventricular assist device insertion is associated with subsequent stroke. *J Heart Lung Transplant* 2015;34:503-8.
71. Kato TS, Schulze PC, Yang J, et al. Pre-operative and post-operative risk factors associated with neurologic complications in patients with advanced heart failure supported by a left ventricular assist device. *J Heart Lung Transplant* 2012;31:1-8.
72. van den Bergh WM, Lansink-Hartgring AO, van Duijn AL, Engström AE, Lahpor JR, Slooter AJ. Thromboembolic stroke in patients with a HeartMate-II left ventricular assist device—the role of anticoagulation. *J Cardiothorac Surg* 2015;10:128.
73. Masotti L, Di Napoli M, Godoy DA, et al. The practical management of intracerebral hemorrhage associated with oral anticoagulant therapy. *Int J Stroke* 2011;6:228-40.
74. Sarode R, Milling TJ Jr, Refaai MA, et al. Efficacy and safety of a 4-factor prothrombin complex concentrate in patients on vitamin K antagonists presenting with major bleeding: a randomized, plasma-controlled, phase IIIb study. *Circulation* 2013;128:1234-43.
75. Refaai MA, Goldstein JN, Lee ML, Durn BL, Milling TJ Jr, Sarode R. Increased risk of volume overload with plasma compared with four-factor prothrombin complex concentrate for urgent vitamin K antagonist reversal. *Transfusion* 2015;55:2722-9.
76. Krstic A, O'Carroll C, Lanza LA, Steidley DE, Staley LL, Cartin-Ceba R. 1276: simultaneous LVAD thrombosis and ischemic stroke treated successfully with alteplase. *Crit Care Med* 2015;43:321.
77. Hannan MM, Husain S, Mattner F, et al. Working formulation for the standardization of definitions of infections in patients using ventricular assist devices. *J Heart Lung Transplant* 2011;30:375-84.
78. Monkowski DH, Axelrod P, Fekete T, Hollander T, Furukawa S, Samuel R. Infections associated with ventricular assist devices: epidemiology and effect on prognosis after transplantation. *Transpl Infect Dis* 2007;9:114-20.
79. Pagani FD, Miller LW, Russell SD, et al. Extended mechanical circulatory support with a continuous-flow rotary left ventricular assist device. *J Am Coll Cardiol* 2009;54:312-21.
80. Sharma V, Deo SV, Stulak JM, et al. Driveline infections in left ventricular assist devices: implications for destination therapy. *Ann Thorac Surg* 2012;94:1381-6.
81. Topkara VK, Kondareddy S, Malik F, et al. Infectious complications in patients with left ventricular assist device: etiology and outcomes in the continuous-flow era. *Ann Thorac Surg* 2010;90:1270-7.
82. Dang NC, Topkara VK, Kim BT, Lee BJ, Remoli R, Naka Y. Nutritional status in patients on left ventricular assist device support. *J Thorac Cardiovasc Surg* 2005;130:e3-4.
83. Grosman-Rimon L, Billia F, Fuks A, et al. New therapy, new challenges: the effects of long-term continuous flow left ventricular assist device on inflammation. *Int J Cardiol* 2016;215:424-30.
84. Butler J, Howser R, Portner PM, Pierson RN 3rd. Body mass index and outcomes after left ventricular assist device placement. *Ann Thorac Surg* 2005;79:66-73.
85. Deng MC, Erren M, Tjan TD, et al. Left ventricular assist system support is associated with persistent inflammation and temporary immunosuppression. *Thorac Cardiovasc Surg* 1999;47:326-31.

86. Grosman-Rimon L, Jacobs I, Tumiati LC, et al. Longitudinal assessment of inflammation in recipients of continuous-flow left ventricular assist devices. *Can J Cardiol* 2015;31:348-56.
87. Erba PA, Sollini M, Conti U, et al. Radiolabeled WBC scintigraphy in the diagnostic workup of patients with suspected device-related infections. *JACC Cardiovasc Imaging* 2013;6:1075-86.
88. Califano S, Pagani FD, Malani PN. Left ventricular assist device-associated infections. *Infect Dis Clin North Am* 2012;26:77-87.
89. Kim J, Feller ED, Chen W, Dilsizian V. FDG PET/CT imaging for LVAD associated infections. *JACC Cardiovasc Imaging* 2014;7:839-42.
90. Roman CD, Habibian MR, Martin WH. Identification of an infected left ventricular assist device after cardiac transplant by indium-111 WBC scintigraphy. *Clin Nucl Med* 2005;30:16-7.
91. Levy DT, Minamoto GY, Da Silva R, et al. Role of gallium SPECT-CT in the diagnosis of left ventricular assist device infections. *ASAIO J* 2015;61:e5-10.
92. Akin S, Muslem R, Constantinescu AA, et al. 18F-FDG PET/CT in the diagnosis and management of continuous flow left ventricular assist device infections: a case series and review of the literature. *ASAIO J* 2018;64:e11-9.
93. Aslam S, Xie R, Cowger J, et al. Bloodstream infections in mechanical circulatory support device recipients in the International Society of Heart and Lung Transplantation Mechanically Assisted Circulation Support Registry: epidemiology, risk factors, and mortality. *J Heart Lung Transplant* 2018;37:1013-20.
94. Nienaber JJ, Kusne S, Riaz T, et al. Clinical manifestations and management of left ventricular assist device-associated infections. *Clin Infect Dis* 2013;57:1438-48.
95. Husain S, Sole A, Alexander BD, et al. The 2015 International Society for Heart and Lung Transplantation Guidelines for the management of fungal infections in mechanical circulatory support and cardiothoracic organ transplant recipients: executive summary. *J Heart Lung Transplant* 2016;35:261-82.
96. Baddour LM, Wilson WR, Bayer AS, et al. Infective endocarditis: diagnosis, antimicrobial therapy, and management of complications: a statement for healthcare professionals from the Committee on Rheumatic Fever, Endocarditis, and Kawasaki Disease, Council on Cardiovascular Disease in the Young, and the Councils on Clinical Cardiology, Stroke, and Cardiovascular Surgery and Anesthesia, American Heart Association: endorsed by the Infectious Diseases Society of America. *Circulation* 2005;111:e394-434.
97. Sandoe JAT, Barlow G, Chambers JB, et al. Guidelines for the diagnosis, prevention and management of implantable cardiac electronic device infection. Report of a joint Working Party project on behalf of the British Society for Antimicrobial Chemotherapy (BSAC, host organization), British Heart Rhythm Society (BHRS), British Cardiovascular Society (BCS), British Heart Valve Society (BHVS) and British Society for Echocardiography (BSE). *J Antimicrob Chemother* 2015;70:325-59.
98. Najjar SS, Slaughter MS, Pagani FD, et al. An analysis of pump thrombus events in patients in the HeartWare ADVANCE bridge to transplant and continued access protocol trial. *J Heart Lung Transplant* 2014;33:23-34.
99. Mehra MR, Stewart GC, Uber PA. The vexing problem of thrombosis in long-term mechanical circulatory support. *J Heart Lung Transplant* 2014;33:1-11.
100. Maltais S, Kilic A, Nathan S, et al. PREVENTion of HeartMate II pump thrombosis through clinical management: the PREVENT multi-center study. *J Heart Lung Transplant* 2017;36:1-12.
101. Tchanchaleishvili V, Sagebin F, Ross RE, Hallinan W, Schwarz KQ, Massey HT. Evaluation and treatment of pump thrombosis and hemolysis. *Ann Cardiothorac Surg* 2014;3:490-5.
102. Goldstein DJ, John R, Salerno C, et al. Algorithm for the diagnosis and management of suspected pump thrombus. *J Heart Lung Transplant* 2013;32:667-70.
103. Sylvia LM, Ordway L, Pham DT, DeNofrio D, Kiernan M. Bivalirudin for treatment of LVAD thrombosis: a case series. *ASAIO J* 2014;60:744-7.
104. Chetan D, Buchholz H, Bauman M, Anand V, Holinski P, Conway J. Successful treatment of pediatric ventricular assist device thrombosis. *ASAIO J* 2018;64:e28-32.
105. Hasin T, Deo S, Maleszewski JJ, et al. The role of medical management for acute intravascular hemolysis in patients supported on axial flow LVAD. *ASAIO J* 2014;60:9-14.
106. Upshaw JN, Kiernan MS, Morine KJ, Kapur NK, DeNofrio D. Incidence, management, and outcome of suspected continuous-flow left ventricular assist device thrombosis. *ASAIO J* 2016;62:33-9.
107. Levin AP, Saeed O, Willey JZ, et al. Watchful waiting in continuous-flow left ventricular assist device patients with ongoing hemolysis is associated with an increased risk for cerebrovascular accident or death. *Circ Heart Fail* 2016;9:e002896.
108. Kirklin JK, Naftel DC, Pagani FD, et al. Seventh INTERMACS annual report: 15,000 patients and counting. *J Heart Lung Transplant* 2015;34:1495-504.
109. Waller AH, Dunne R, Stewart GC, et al. Evaluation of bend relief disconnection in patients supported by a HeartMate II left ventricular assist device. *Circ Cardiovasc Imaging* 2014;7:844-8.
110. Mehra MR, Salerno C, Naka Y, et al. A tale of the twist in the outflow graft: an analysis from the MOMENTUM 3 trial. *J Heart Lung Transplant* 2018;37:1281-4.
111. Kalavrouziotis D, Tong MZ, Starling RC, et al. Percutaneous lead dysfunction in the HeartMate II left ventricular assist device. *Ann Thorac Surg* 2014;97:1373-8.
112. Schima H, Stoiber M, Schlöglhofer T, Hartner Z, Haberl T, Zimpfer D. Repair of left ventricular assist device driveline damage directly at the transcutaneous exit site. *Artif Organs* 2014;38:422-5.
113. Wever-Pinzon O, Givens RC, Flannery M, Naka Y, Jorde UP. Repetitive HeartMate II pump stoppage induced by transitioning from battery to main power source: the short-to-shield phenomenon. *J Heart Lung Transplant* 2015;34:270-1.
114. Burke MA, Givertz MM. Assessment and management of heart failure after left ventricular assist device implantation. *Circulation* 2014;129:1161-6.
115. Kornberger A, Stock UA, Risteski P, Beiras Fernandez A. Left ventricular non-compaction cardiomyopathy and left ventricular assist device: a word of caution. *J Cardiothorac Surg* 2016;11:108.
116. Abraham J, Remick JD, Caulfield T, et al. Left ventricular assist device outflow cannula obstruction treated with percutaneous endovascular stenting. *Circ Heart Fail* 2015;8:229-30.
117. Baker WL, Radojevic J, Gluck JA. Systematic review of phosphodiesterase-5 inhibitor use in right ventricular failure following left ventricular assist device implantation. *Artif Organs* 2016;40:123-8.
118. Rao P, Smith R, Khalpey Z. Potential impact of the proposed revised UNOS thoracic organ allocation system. *Semin Thorac Cardiovasc Surg* 2018;30:129-33.
119. Morris MF, Staley LL, Arabia FA, DeValeria PA, Collins JM. Abdominal X-ray imaging for detection of left ventricular assist device driveline damage. *J Heart Lung Transplant* 2012;31:1313-5.
120. Li JS, Sexton DJ, Mick N, et al. Proposed modifications to the Duke criteria for the diagnosis of infective endocarditis. *Clin Infect Dis* 2000;30:633-8.